

Causation: Recurrent collagenous colitis following repeated use of NSAIDs

Mohammed Y Al-Ghamdi MD¹, Dickran A Malatjalian MD²,
Sander Veldhuyzen van Zanten MD¹

MY Al-Ghamdi, DA Malatjalian, S Veldhuyzen van Zanten.
Causation: Recurrent collagenous colitis following repeated use of NSAIDs. *Can J Gastroenterol* 2002;16(12):861-862.

A case in which a patient who on two occasions developed watery diarrhea and proven collagenous colitis shortly after taking nonsteroidal anti-inflammatory drugs is described. The case report suggests a causal relationship.

Key Words: *Causation; Collagenous colitis; NSAIDs*

Nonsteroidal anti-inflammatory drugs (NSAIDs) are medications frequently used mainly for pain relief and musculoskeletal conditions. Collagenous colitis is a rare inflammatory disorder of the mucosa with known associations but without an accepted pathogenesis. It usually presents with watery diarrhea. During colonoscopy the macroscopic appearance of the colonic mucosa is normal. Histological examination of colonic biopsies shows a mucosal inflammatory process with a characteristic thickened subepithelial collagen band (1). NSAIDs have been postulated as a possible cause for collagenous colitis (1,2). We report a case of recurrent collagenous colitis, which followed the use of two different NSAIDs. Symptoms developed following the start of the NSAIDs and subsided upon their discontinuation, suggesting a causal relationship.

CASE PRESENTATION

An 80-year-old woman with a long-standing history of osteoporosis presented with a history of new onset large volume watery diarrhea. She had up to eight bowel movements per day without mucus or blood. It was associated with

Causalité : Cas de colite collagénique récurrente suivant l'usage répété d'AINS

RÉSUMÉ : On décrit le cas d'un patient qui, à deux occasions, a présenté une diarrhée aqueuse et une colite collagénique avérée peu après avoir pris des anti-inflammatoires non stéroïdiens (AINS). Le rapport de cas laisse supposer une relation de causalité.

crampy lower abdominal pain. The rest of her medical history was unremarkable. The only medication she was taking was diclofenac 50 mg orally twice daily for osteoarthritis prescribed by her family doctor six weeks before presentation.

Her stool cultures for pathogens including *Clostridium difficile*, *Salmonella* species, *Shigella* species, *Campylobacter* species and parasites were negative. Complete blood count, electrolytes, blood urea nitrogen and creatinine were all normal. Colonoscopy showed a normal mucosa throughout the colon. Histological examination of randomly taken biopsies from right, transverse and left colon showed a markedly thickened collagenous band ranging from 15 to 60 µm in thickness and associated with mild nonspecific mononuclear inflammatory cells in the lamina propria in keeping with collagenous colitis (Figure 1). Following the discontinuation of diclofenac her symptoms resolved completely within a few weeks.

Two years later the patient was seen again because of watery diarrhea. She had been started on ketoprofen 200 mg once a day four weeks before the diarrhea started.

¹Division of Gastroenterology and ²Department of Anatomical Pathology, Dalhousie University, Queen Elizabeth II Health Sciences Centre, Halifax, Nova Scotia

Correspondence: Dr Sander Veldhuyzen van Zanten, Department of Medicine, Room 928 Centennial Building, Victoria General Site, Queen Elizabeth II Health Sciences Centre, Halifax, Nova Scotia B3H 2Y9. Telephone 902-473-3215, fax 902-473-4406, e-mail zanten@dal.ca
Received for publication August 8, 2001. Accepted September 24, 2002

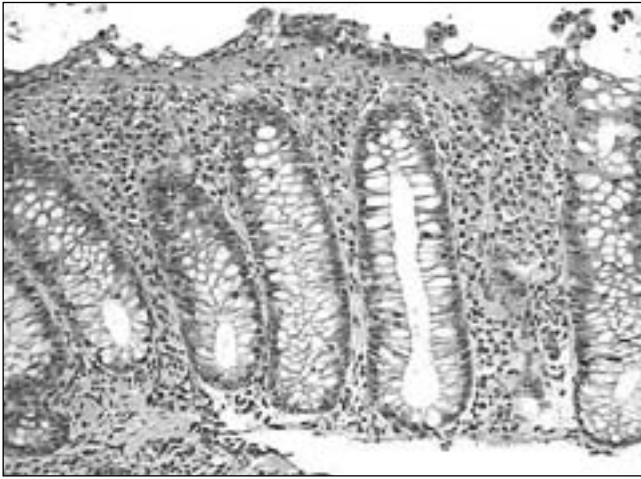


Figure 1) Hematoxylin and eosin stained section of colonic mucosa showing the subepithelial collagen layer, which is substantially increased at 60 µm in thickness

Colonoscopy was performed six weeks following the start of ketoprofen. The mucosa macroscopically again looked completely normal and random biopsies confirmed collagenous colitis. The patient discontinued ketoprofen and her diarrhea stopped in two weeks.

This time an upper gastrointestinal endoscopy was also performed and was normal. Biopsies taken from the antrum and body and second part of the duodenum all were normal. There was no evidence of villous atrophy or lymphocytic gastritis. Her other medications at this time were etidronate disodium for osteoporosis and acetylsalicylic acid 80 mg. She had been recently started on ranitidine.

Two years later the patient was referred because of iron deficiency with a hemoglobin of 83 g/L. She had no bowel symptoms at the time and, in particular, no diarrhea. She underwent both gastroscopy and colonoscopy, both of which were normal. Colonic biopsies were unremarkable.

DISCUSSION

Microscopic colitis consists of different disease entities, including collagenous colitis and lymphocytic colitis, or as a mixed form (1-4). The first case of collagenous colitis was described in 1976 (5). It is more common in women than men, while the sex distribution is equal in lymphocytic coli-

tis. This disease can occur in children (6). The cause of collagenous colitis is unknown. Possible contributing causes are celiac disease, diabetes, thyroiditis, rheumatoid arthritis and scleroderma (7-9). Bile acid malabsorption may also be associated with collagenous colitis (9), and the use of bile acid resin may improve the symptoms of collagenous colitis (9). NSAID use has been suggested as a cause of collagenous colitis (1,2).

In the case control study by Riddell et al (1), 31 patients with collagenous colitis were compared with 31 matched control patients with irritable bowel syndrome or diverticular disease in whom colonoscopy with biopsies had been performed. Long term use (more than six months) of NSAIDs was significantly more common among patients with collagenous colitis (1). The same investigators demonstrated that in the majority of cases the diagnosis is made when multiple biopsies are taken from the rectosigmoid area (10). However, the disease may be patchy. If left sided biopsies show a normal collagen band but an inflamed mucosa, total colonoscopy with biopsies from the right colon may be required to establish the diagnosis (10,11).

Our case strongly implicates NSAID use as the cause of the development of collagenous colitis in this patient because both diclofenac and ketoprofen use led to a clinical syndrome of watery diarrhea. Biopsies confirmed the diagnosis. Symptoms resolved following discontinuation of the NSAIDs. With ketoprofen the clinical symptom of watery diarrhea appeared within four weeks after the drug was started, and histological evidence of collagenous colitis was present when colonoscopy was performed two weeks later. This is shorter than the average duration of NSAID use reported in the study by Riddell et al (1). Colonic biopsies are required to make the diagnosis. Ideally, to prove causation, colonic biopsies should be repeated after withdrawal of the medication to prove normalization of the histological abnormalities. However, this was not done because the patient was clinically well. She did have a third colonoscopy two years after the ketoprofen use for the evaluation of anemia. This time the colonic biopsies were normal. This strongly supports the association between NSAID use and collagenous colitis (1)

We conclude that NSAIDs use should be considered as a cause of collagenous colitis.

REFERENCES

- Riddell RH, Tanaka M, Mazzoleni G. Non-steroidal anti-inflammatory drugs: A possible cause of collagenous colitis, a case control study. *Gut* 1992;33:683-6.
- Giardiello FM, Hansen FC III, Lazenby AJ, et al. Collagenous colitis in setting of nonsteroidal antiinflammatory drugs and antibiotics. *Dig Dis Sci* 1990;35:257-60.
- Versess B, Lofberg R, Bergman L. Microscopic colitis syndrome. *Gut* 1995;36:880-6.
- Bohr J, Olesen M, Tysk C, Jarnerot G. Collagenous and lymphocytic colitis: A clinical and histopathological review. *Can J Gastroenterol* 2000;14:943-7.
- Lindstrom CG. Collagenous colitis with watery diarrhoea – A new entity. *Pathol Eur* 1976;11:87-9.
- Perisic VN, Kokai G. Diarrhoea caused by collagenous colitis. *Arch Dis Child* 1989;64:867-8.
- Esselinck W, Bernard R, Colin JR, Melange M. Juvenile scleroderma and collagenous colitis. *J Rheumatol* 1989;16:834-6.
- Dubois RN, Lazenby AJ, Yardley JH, Hendrix TR, Bayless TM, Giardiello FM. Lymphocytic enterocolitis in a patient with refractory sprue. *JAMA* 1989;262:935-7.
- Ung KA, Gillberg R, Kilander A, Abrahamsson H. Role of bile acids and bile acid binding agents in patients with collagenous colitis. *Gut* 2000;46:170-5.
- Tanaka M, Mazzoleni G, Riddell RH. Distribution of collagenous colitis: Utility of flexible sigmoidoscopy. *Gut* 1992;33:65-70.
- Lazenby AJ, Yardley JH, Giardiello FM, Bayless TM. Pitfalls in the diagnosis of collagenous colitis: Experience with 75 cases from a registry of collagenous colitis at the Johns Hopkins Hospital. *Hum Pathol* 1990;21s:905-10.



Hindawi
Submit your manuscripts at
<http://www.hindawi.com>

