

## Case Report

# Pulmonary Hypertension and Hypcholesterolemia Secondary to Thyrotoxicosis

Narangoda Liyanage Ajantha Shyamali <sup>1</sup> and Chandrike Ponnampereuma <sup>2</sup>

<sup>1</sup>University of Sri Jayawardenepura, Gangodawila, Nugegoda, Sri Lanka

<sup>2</sup>National Hospital of Sri Lanka, Colombo 10, Sri Lanka

Correspondence should be addressed to Narangoda Liyanage Ajantha Shyamali; [ajaliyanage@yahoo.com](mailto:ajaliyanage@yahoo.com)

Received 16 September 2020; Revised 31 October 2020; Accepted 7 November 2020; Published 16 November 2020

Academic Editor: Lucy Mastrandrea

Copyright © 2020 Narangoda Liyanage Ajantha Shyamali and Chandrike Ponnampereuma. This is an open access article distributed under the Creative Commons Attribution License, which permits unrestricted use, distribution, and reproduction in any medium, provided the original work is properly cited.

**Background.** Thyroid disorders commonly affect the cardiovascular system. Thyrotoxicosis leading to pulmonary hypertension has been increasingly reported during recent years. Thyroid dysfunction affects the lipid metabolism, and thyrotoxicosis can be associated with low lipid levels. Thyrotoxicosis presenting with right ventricular dysfunction is rare, and only few cases had been reported. **Case Presentation.** A 53-year-old woman presented with progressive shortness of breath and swelling of body for four months. Examination showed generalized oedema and a systolic murmur over the left sternal border. Transthoracic echocardiography confirmed pulmonary hypertension with tricuspid regurgitation. Investigations revealed thyrotoxicosis and very low cholesterol levels. Diagnosis of Graves' disease was confirmed with detection of thyrotropin receptor antibodies. Pulmonary pressure was normalized six months after antithyroid therapy. **Conclusion.** Thyrotoxicosis is a recognized cause of reversible pulmonary hypertension and acquired hypcholesterolemia. However, most clinicians are not aware of these associations. This case illustrates the importance of assessing thyroid function in patients presenting with pulmonary hypertension.

## 1. Introduction

Thyrotoxicosis is well known to associate with left ventricular dysfunction due to long-standing effects of thyroid hormones. However, the association of hyperthyroidism with right ventricular dysfunction secondary to pulmonary hypertension has been reported in the literature since 1980 [1]. The exact mechanism of pulmonary hypertension in thyrotoxicosis is ill-defined [2, 3]. Several studies have reported the resolution of pulmonary hypertension secondary to thyrotoxicosis with antithyroid therapy [4]. The association of hypothyroidism with hyperlipidemia has been well known for a long period. However, low cholesterol level secondary to thyrotoxicosis is not widely appreciated. Only few cases of Graves' thyrotoxicosis with pulmonary hypertension and hyperlipidemia have been reported in the literature.

## 2. Case Presentation

A 53-year-old previously healthy woman presented with fever for 3 days associated with a four-month history of progressive shortness of breath and generalized body swelling. She has also noted increased sweating which she considered as a perimenopausal symptom. On examination, she was febrile with a heart rate of 101/min and oxygen saturation of 98% on room air. She had bilateral ankle oedema and extensive abdominal wall oedema. Jugular venous pressure was elevated, and there was a pansystolic murmur over the left sternal border. Respiratory system examination was clinically normal.

Her basic blood investigations of full blood count, erythrocyte sedimentation rate, C-reactive protein levels, renal function tests, and liver function tests were normal. She was found to have low cholesterol levels with total

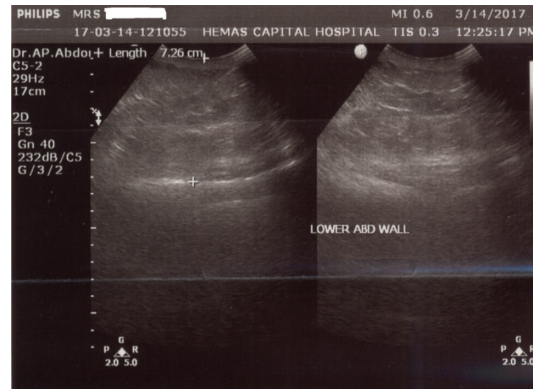
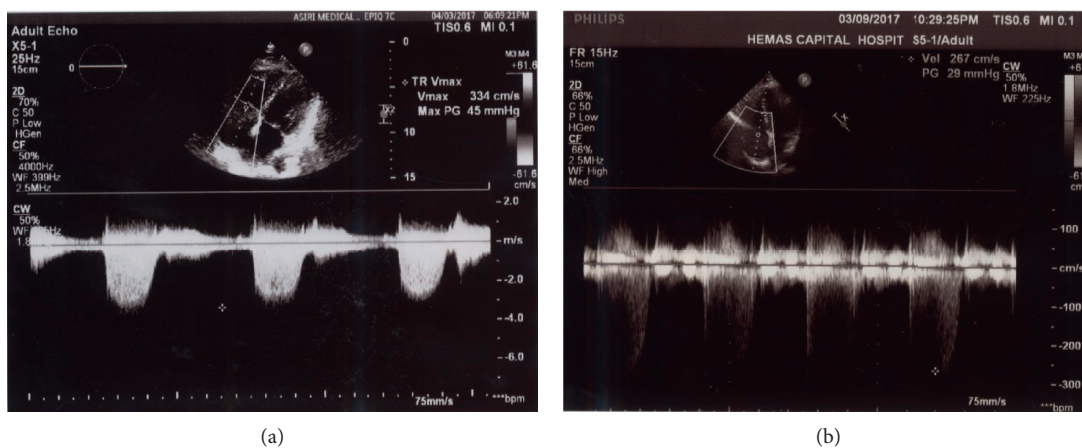


FIGURE 1: Ultrasound scan of the abdomen showing extensive abdominal wall oedema.



(a)

(b)

FIGURE 2: Transthoracic echocardiography demonstrating pulmonary artery pressures before (a) and after (b) the treatment of thyrotoxicosis.

cholesterol of 61 mg/dl (normal range: 140–239), low-density lipoprotein cholesterol (LDLC) of 26 mg/dl (normal range: 75–159), and high-density lipoprotein cholesterol (HDL) of 20 mg/dl (normal range: 35–85). Thyroid-stimulating hormone (TSH) level was 0.004  $\mu$ IU/ml (normal range: 0.4–4.0) with free thyroxine (FT4) 5.48 ng/dl (normal range: 0.89–1.76) and free triiodothyronine (FT3) 11.48 pg/dl (normal range: 1.5–4.1). TSH receptor antibodies were positive with 4.39 IU/L (normal < 2 IU/L). Ultrasound of the thyroid showed diffusely enlarged glands with increased vascularity, and ultrasound scan of the abdomen revealed marked lower abdominal wall oedema without organomegaly (Figure 1). Transthoracic echocardiography showed right ventricular enlargement with tricuspid regurgitation. The systolic pulmonary artery pressure gradient was 45 mmHg (normal < 25 mmHg) (Figure 2(a)).

Graves' thyrotoxicosis was diagnosed, and she was started on antithyroid medication. She underwent computed tomographic pulmonary angiography (CT-PA) ten days after starting thyrostatic drugs which did not show evidence of chronic thromboembolic pulmonary hypertension or abnormalities of lung parenchyma. After six months of treatment, her symptoms improved. The systolic pulmonary artery pressure gradient was reduced to 29 mmHg in

repeated transthoracic echocardiography (Figure 2(b)). TSH level increased to 0.48  $\mu$ IU/ml with normalization of thyroid hormone levels. Her serum lipid levels returned to normal with total cholesterol of 185 mg/dl, LDLC of 109 mg/dl, and HDLC of 61 mg/dl.

### 3. Discussion

The association of thyrotoxicosis with right ventricular dysfunction was first reported in the literature in 1973 [5]. Thyrotoxicosis as a cause for pulmonary hypertension and reduction of pulmonary artery pressure with treatment of antithyroid medication have been clearly established recently [6, 7]. Therefore, most clinicians are not aware of this important association.

In a study of 23 patients with Graves' thyrotoxicosis, 65% of patients had pulmonary hypertension which normalized with definitive treatment, and a recent single-center cross-sectional study carried out in Ethiopia showed that 30% of patients with hyperthyroidism have echocardiographic evidence of pulmonary hypertension [4, 8]. Although the underlying pathophysiology for this complication is unclear, several mechanisms have been hypothesized: endothelial injury secondary to high cardiac output, immune-mediated

endothelial damage, and enhanced metabolism of intrinsic pulmonary vasodilators [3, 9].

Increased expression of low-density lipoprotein (LDL) receptors and activity of lipoprotein lipase by thyroid hormones decrease the circulating levels of lipoproteins. Consequently, decreased levels of HDLC and LDLC are seen in patients with hyperthyroidism [10, 11]. The action of thyroid hormones in the liver is responsible for the reduction of LDLC levels, which is caused by enhanced transcription of LDL receptors in the liver. Therefore, the extent of LDLC level reduction is proportional to free thyroid hormone levels [11]. Hyperthyroidism is recognized as a significant cause of acquired hypocholesterolemia and unanticipated improvement of lipid levels in hyperlipidemic patients [12].

Thyrotoxicosis is an overlooked, reversible cause of pulmonary hypertension, and there is a high prevalence of pulmonary hypertension among hyperthyroid patients [13]. Thus, patients presenting with thyrotoxicosis and dyspnea should be screened for pulmonary hypertension [14]. All clinicians should be aware of this association, and this case highlights the importance of assessing thyroid function tests in patients with pulmonary hypertension.

## Abbreviations

LDLC: Low-density lipoprotein cholesterol  
 HDLC: High-density lipoprotein cholesterol  
 TSH: Thyroid-stimulating hormone  
 FT4: Free thyroxine  
 FT3: Free triiodothyronine.

## Data Availability

The clinical details and results of investigations are documented in bed head tickets. Bed head tickets are available in the record room of Asiri Medical Private Hospital of Sri Lanka. All the original reports are with the patient.

## Consent

The authors obtained written informed consent from the patient to report and publish about her illness anonymously.

## Conflicts of Interest

The authors declare that they have no conflicts of interest.

## Authors' Contributions

NLA Shyamali was involved in the history taking, examination, diagnosis, and management of the patient's condition and prepared the manuscript for publication. C Ponnampereuma performed and reported echocardiography and was involved in diagnosis and management of the patient's condition. All authors read and approved the final manuscript.

## Acknowledgments

The authors acknowledge the support from the staff of Asiri Medical Hospital, Sri Lanka, in the management of this patient's condition.

## References

- [1] M. Shimazaki, T. Mitsuhashi, and K. Hasegawa, "Idiopathic pulmonary hypertension associated with hyperthyroidism—an autopsy case," *Nihon Rinsho. Japanese Journal of Clinical Medicine*, vol. 38, no. 3, pp. 1783–1786, 1980.
- [2] M. Conradie, C. Koegelenberg, M. Conradie, B. Ascott-Evans, and F. Hough, "Pulmonary hypertension and thyrotoxicosis," *Journal of Endocrinology, Metabolism and Diabetes of South Africa*, vol. 17, no. 2, pp. 101–104, 2014.
- [3] F. Rashidi, H. Sate, E. Faraji, and S. Tahsini Tekantapeh, "Thyrotoxicosis presenting as exertional dyspnea and pulmonary hypertension: case report and review of literature," *SAGE Open Medical Case Reports*, vol. 5, 2017.
- [4] M. Marvisi, P. Zambrelli, M. Brianti, G. Civardi, R. Lampugnani, and R. Delsignore, "Pulmonary hypertension is frequent in hyperthyroidism and normalizes after therapy," *European Journal of Internal Medicine*, vol. 17, no. 4, pp. 267–271, 2006.
- [5] M. J. Dougherty and E. Craige, "Apathetic hyperthyroidism presenting as tricuspid regurgitation," *Chest*, vol. 63, no. 5, pp. 767–772, 1973.
- [6] S. L. Teasdale, W. J. Inder, M. Stowasser, and T. Stanton, "Hyperdynamic right heart function in Graves' hyperthyroidism measured by echocardiography normalises on restoration of euthyroidism," *Heart, Lung and Circulation*, vol. 26, no. 6, pp. 580–585, 2017.
- [7] C. S. Singarayay, F. S. Hui, N. Cheong, and G. S. En, "Right ventricular dysfunction and pulmonary hypertension: a neglected presentation of thyrotoxicosis," *Endocrinology, Diabetes & Metabolism Case Reports*, vol. 2018, 2018.
- [8] H. A. Mulatu, "Pattern and presentation of thyro-cardiac disease among patients with hyperthyroidism attending a tertiary hospital in Ethiopia: a cross sectional study," *Ethiopian Journal of Health Sciences*, vol. 29, no. 1, pp. 887–894, 2019.
- [9] M. O. Hegazi, A. El Sayed, and H. El Ghousein, "Pulmonary hypertension responding to hyperthyroidism treatment," *Respirology*, vol. 13, no. 6, pp. 923–925, 2008.
- [10] Y. Chen, X. Wu, R. Wu et al., "Changes in profile of lipids and adipokines in patients with newly diagnosed hypothyroidism and hyperthyroidism," *Scientific Reports*, vol. 6, Article ID 26174, 2016.
- [11] Y. Bonde, O. Breuer, D. Lütjohann, S. Sjöberg, B. Angelin, and M. Rudling, "Thyroid hormone reduces PCSK9 and stimulates bile acid synthesis in humans," *Journal of Lipid Research*, vol. 55, no. 11, pp. 2408–2415, 2014.
- [12] C. V. Rizos, M. Elisaf, and E. Liberopoulos, "Effects of thyroid dysfunction on lipid profile," *The Open Cardiovascular Medicine Journal*, vol. 5, no. 1, pp. 76–84, 2011.
- [13] E. Berta, I. Lengyel, S. Halmi et al., "Hypertension in thyroid disorders," *Frontiers in Endocrinology*, vol. 10, p. 482, 2019.
- [14] S. Vallabhajosula, S. Radhi, R. Alalawi, R. Raj, K. Nugent, and C. Cevik, "Hyperthyroidism and pulmonary hypertension: an important association," *The American Journal of the Medical Sciences*, vol. 342, no. 6, pp. 507–512, 2011.