

## Case Report

# Preaxial Polydactyly of the Foot: Variable Expression of Trisomy 13 in a Case from Central Africa

Sébastien Mbuyi-Musanzayi,<sup>1,2</sup> Aimé Lumaka,<sup>3,4</sup> Bienvenu Yogolelo Asani,<sup>2,5</sup>  
Toni Lubala Kasole,<sup>2,6</sup> Prosper Lukusa Tshilobo,<sup>3,4</sup> Prosper Kalenga Muenze,<sup>2,7</sup>  
François Tshilombo Katombe,<sup>1</sup> and Koenraad Devriendt<sup>3</sup>

<sup>1</sup> Department of Surgery, University Hospital, University of Lubumbashi, P.O. Box 1825, Lubumbashi, Democratic Republic of Congo

<sup>2</sup> Center for Human Genetics, Faculty of Medicine, University of Lubumbashi, P.O. Box 1825, Lubumbashi, Democratic Republic of Congo

<sup>3</sup> Center for Human Genetics, University Hospitals, KU Leuven, UZ Leuven, Campus Gasthuisberg, Herestraat 49, P.O. Box 602, 3000 Leuven, Belgium

<sup>4</sup> Department of Pediatrics, University Hospitals, University of Kinshasa, P.O. Box 123, Kin XI, Kinshasa, Democratic Republic of Congo

<sup>5</sup> Department of Ophthalmology, University Hospital, University of Lubumbashi, P.O. Box 1825, Lubumbashi, Democratic Republic of Congo

<sup>6</sup> Department of Pediatrics, University Hospital, University of Lubumbashi, P.O. Box 1825, Lubumbashi, Democratic Republic of Congo

<sup>7</sup> Department of Gynecology, University Hospital, University of Lubumbashi, P.O. Box 1825, Lubumbashi, Democratic Republic of Congo

Correspondence should be addressed to Koenraad Devriendt; [koenraad.devriendt@uzleuven.be](mailto:koenraad.devriendt@uzleuven.be)

Received 6 June 2014; Revised 5 August 2014; Accepted 9 August 2014; Published 1 September 2014

Academic Editor: Philip D. Cotter

Copyright © 2014 Sébastien Mbuyi-Musanzayi et al. This is an open access article distributed under the Creative Commons Attribution License, which permits unrestricted use, distribution, and reproduction in any medium, provided the original work is properly cited.

Trisomy 13 is a chromosomal disorder characterized by a severe clinical picture of multiple congenital anomalies. We here describe the clinical and genetic features and prognosis observed in a newborn with trisomy 13 from Central Africa. He presented the rare feature of preaxial polydactyly of the feet.

## 1. Introduction

Trisomy 13 (also known as Patau syndrome) is the third most common autosomal trisomy [1, 2]. The prevalence is between 1:10,000 and 1:20,000 live births [3], but it is estimated that the frequency of trisomy 13 is 100 times higher in spontaneous abortions [4, 5]. This chromosomal disorder has a characteristic phenotype consisting of multiple congenital anomalies [6], with a classical clinical triad of microphthalmia or anophthalmia, cleft lip and/or palate, and postaxial polydactyly. However, other anomalies are frequently associated [2, 7]. The objective of this report is to describe the clinical features and prognosis in a Congolese newborn with trisomy 13 and to illustrate the occurrence of a rare manifestation in this syndrome, preaxial polydactyly of the foot.

## 2. Case Report

The patient, a male, was referred at an age of two days. He was born at 40 weeks of gestation via a normal spontaneous vaginal delivery with birth weight 3250 g (−0.5 SD). His mother was 25 years old and father was 32 years old; both were healthy and unrelated. Family history was unremarkable. Prenatal ultrasound was not performed. He presented median cleft lip and palate, microcephaly (29 cm—2.6 SD), bilateral anophthalmia, a posterior scalp defect, short neck, micropenis, and bilateral cryptorchidism (Figure 1). He had bilateral postaxial polydactyly of his hands. Of interest, he also had bilateral preaxial polydactyly of the first toes. The child was hypotonic and died at age of 5 days from acute respiratory distress.

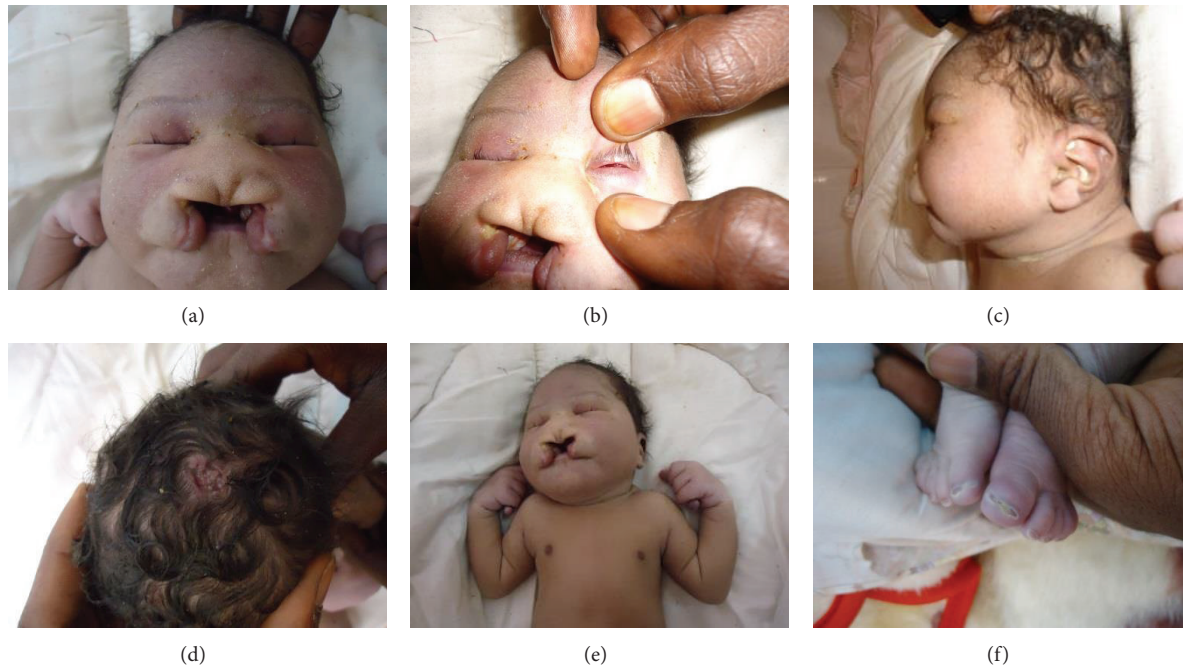

FIGURE 1: Craniofacial abnormalities observed in the patient. Note (a) median cleft lip and palate, (b) anophthalmia, (c) low-set ears, (d) aplasia cutis/scalp defect, (e) postaxial polydactyly on the hands, and (f) preaxial polydactyly of the feet.

### 3. Methods

Genomic DNA was isolated using standard protocols from the peripheral blood leukocytes and screened for copy number alterations using the Oxford Gene Technology 8 × 60k Array Platform Custom Design (Catalogue number 027216). Array CGH results were interpreted using Oxford Gene Technology CytoSure Interpret Software\_v.3.3.2 (OGT CytoSure, OGT Oxford, UK). All genome coordinates were according to NCBI human genome build 19 (hg19 Feb 2009). We performed array-CGH, which revealed trisomy 13: arr 13q12.11-q34 (20,407,270–115,092,581) ×3 or a duplication of the entire 94.69 Mb of chromosome 13. No additional CNVs were observed. Since karyotyping is not available in this part of the world, we were not able to exclude a Robertsonian translocation.

### 4. Discussion

We here present the clinical and genetic data in newborn with trisomy 13, diagnosed in the Democratic Republic of Congo. Since its first description by Patau in 1960 [8], trisomy 13 has been recognized as one of the three commonly observed autosomal trisomies observed in live newborns, worldwide. In Central Africa, genetics reports on chromosomal imbalances are scarce, and, to the best of our knowledge, there is only one earlier report on trisomy 13 in the Democratic Republic of Congo, dating from the year 1968 [9]. The case we report here presents the classical triad of cleft lip and palate, postaxial polydactyly, and anophthalmia. Each of these features is observed in 60–80% of cases [6, 10]. The patient had a median cleft lip and palate, with marked hypotelorism, characteristic

of holoprosencephaly, a common finding in trisomy 13. Brain ultrasound scan could not be performed, since the parents could not afford to pay for it. In addition, the patients presented several additional features, commonly observed in trisomy 13, as shown in Table 1. Postaxial polydactyly (especially of the hands) is reported in 52–70% of cases [6, 11–13]. However, the patient presented a very unusual sign: bilateral preaxial polydactyly of the feet. This finding has been reported twice before [6, 14]. While this may be a coincidence, it is tempting to speculate that the expression of this unusual feature in this Congolese boy may be related to its different genetic background. However, we have no firm evidence to support this at present. Postaxial polydactyly, especially of the hands, is a common feature in Africa, with a reported incidence between 10.4/1000 births in South and Central Africa [15, 16] and 22.78/1000 in Nigeria [17]. In contrast to this, preaxial polydactyly is rare in Central Africa as elsewhere (Table 1). The early death of the patient presented here is not unexpected: the median survival of patients with trisomy 13 varies from 2.5 to 10 days [3, 4, 13, 18]. The probability of survival until one month of age is about 28% and only 5–10% survive for one year [1, 3]. The cause of death may be primary apnea, regardless of the presence of a CNS abnormality [1, 5, 19]. Also, recurrent apnea may be related to the common occurrence of a cyanotic heart defect, pulmonary hypertension, congestive heart failure, aspiration pneumonia, gastroesophageal reflux, laryngomalacia, and seizures [20–22]. The case reported here is the first one with trisomy 13 to be reported in Central Africa (with the exception of a report in 1968) [9]. This probably reflects the current lack of teaching and thus interest and knowledge in human genetics and syndromology [23]. Whereas, in most

TABLE 1: Summary of clinical features in trisomy 13.

Study Year	Country	Taylor [10] 1968		Hodes et al. [11] 1978		Moerman et al. [12] 1988		Lin et al. [13] 2007		Petry et al. [6] 2013		Quelin et al. [14] 2014		Patient 2014	
		England	USA	Belgium	Taiwan	Brazil	France	DRC							
Samples (N)		27	19	12	28	30	3	1							
Features		%	%	%	%	%	%	%					%		
Craniofacial															
Abnormal auricles		74	79	25	0	77	0					0	-		
Microphthalmia		70	84	42	54	60	33					33	-		
Anophthalmia		0	11	0	14	10	33					33	+		
Low-set ears		85	0	33	?	47	33					33	+		
Aplasia cutis/scalp defect		0	47	25	29	43	0					0	+		
Microcephaly		59	58	50	61	40	0					0	+		
Cleft palate		67	68	42	?	33	0					0	+		
Cleft lip		56	53	8	?	23	0					0	+		
Short neck		70	16	0	46	30	0					0	+		
Ocular hypotelorism		0	21	17	0	10	0					0	+		
Thorax/abdomen															
Inguinal hernia/umbilical hernia		37	32	-	14	20	0					0	-		
Anogenital															
Cryptorchidism		93	100	50	73	78	0					0	+		
Micropenis		-	5	50	?	30	0					0	+		
Limbs, skin, and neurological															
Postaxial polydactyly hands/feet		70	58	67	64	63	0					0	+		
Single palmar crease		59	0	42	32	33	33					33	-		
Duplicated hallux		-	-	-	-	3	0					0	+		
Capillary hemangioma		56	37	0	14	27	0					0	-		
Mongolian spot		0	0	0	0	0	0					0	-		
Hypertonia/hypotonia		77	16	0	0	33	0					0	+		

industrialized countries, trisomy 13 is diagnosed prenatally, the vast majorities of pregnant women in Central Africa currently do not have access to prenatal ultrasound follow-up and are thus confronted with serious emotional distress when facing an unexpected polymalformed newborn. Early clinical recognition of trisomy 13 at birth remains essential to optimize guidance for care of the child and his family. For instance, one can avoid needless and expensive therapeutic or diagnostic interventions, which is crucial in an environment where access to medical care and investigations is difficult and expensive. Moreover, also in this society, an exact diagnosis offers the opportunity to discuss the cause, refute commonly held mystical and traditional beliefs, and relieve misassigned feelings of guilt [24].

### Conflict of Interests

The authors declare that there is no conflict of interests regarding the publication of this paper.

### Authors' Contribution

Sébastien Mbuyi-Musanazayi was responsible for clinical examination, treatment of the patient, and redaction of the paper; Aimé Lumaka for analysis of array CGH; Bienvenu Yogolelo Asani for ophthalmological examination; Toni Lubala Kasole for clinical examination; Prosper Lukusa Tshilobo for the paper correction; Prosper Kalenga Muenze for paper correction; François Tshilombo Katombe for clinical examination; Koenraad Devriendt for clinical examination, diagnosis, and paper corrections. All coauthors have read, contributed, and approved the paper.


### Acknowledgments

The authors thank the families of the patient for their kind cooperation. The authors thank the Cytogenetics Laboratory of the Center for Human Genetics, KU Leuven, for support. S.M. was supported by a scholarship from Interfaculty Council for Development Cooperation (IRO), KU Leuven and GROS, Holsbeek (Belgium).

### References

- [1] S. A. Rasmussen, L.-Y. C. Wong, Q. Yang, K. M. May, and J. M. Friedman, "Population-based analyses of mortality in trisomy 13 and trisomy 18," *Pediatrics*, vol. 111, no. 4, pp. 777–784, 2003.
- [2] A. C. Duarte, A. I. C. Menezes, E. S. Devens, J. M. Roth, G. L. Garcias, and M. G. Martino-Roth, "Patau syndrome with a long survival. A case report," *Genetics and Molecular Research*, vol. 3, no. 2, pp. 288–292, 2004.
- [3] C. M. Brewer, S. H. Holloway, D. H. Stone, A. D. Carothers, and D. R. FitzPatrick, "Survival in trisomy 13 and trisomy 18 cases ascertained from population based registers," *Journal of Medical Genetics*, vol. 39, no. 9, article e54, 2002.
- [4] M. J. Parker, J. L. S. Budd, E. S. Draper, and I. D. Young, "Trisomy 13 and trisomy 18 in a defined population: epidemiological, genetic and prenatal observations," *Prenatal Diagnosis*, vol. 23, no. 10, pp. 856–860, 2003.
- [5] A. Rios, S. A. Furdon, D. Adams, and D. A. Clark, "Recognizing the clinical features of Trisomy 13 syndrome," *Advances in Neonatal Care*, vol. 4, no. 6, pp. 332–343, 2004.
- [6] P. Petry, J. B. Polli, V. F. Mattos et al., "Clinical features and prognosis of a sample of patients with trisomy 13 (Patau syndrome) from Brazil," *The American Journal of Medical Genetics A*, vol. 161, no. 6, pp. 1278–1283, 2013.
- [7] J. C. Carey, "Perspectives on the care and management of infants with trisomy 18 and trisomy 13: striving for balance," *Current Opinion in Pediatrics*, vol. 24, no. 6, pp. 672–678, 2012.
- [8] K. Patau, D. W. Smith, E. Therman, S. L. Inhorn, and H. P. Wagner, "Multiple congenital anomaly caused by an extra autosome," *The Lancet*, vol. 275, no. 7128, pp. 790–793, 1960.
- [9] G. Cornu, J. P. Lintermans, H. van den Berghe, and R. Eeckels, "Trisomy 17-18 and trisomy 13-15 in the African child," *Journal of Tropical Medicine and Hygiene*, vol. 71, no. 4, pp. 105–109, 1968.
- [10] A. I. Taylor, "Autosomal trisomy syndromes: a detailed study of 27 cases of Edwards' syndrome and 27 cases of Patau's syndrome," *Journal of Medical Genetics*, vol. 5, no. 3, pp. 227–252, 1968.
- [11] M. E. Hodes, J. Cole, C. G. Palmer, and T. Reed, "Trisomy 18 (29 cases) and trisomy 13 (19 cases): a summary," *Birth Defects: Original Article Series Journal*, vol. 14, no. 6, pp. 377–382, 1978.
- [12] P. Moerman, J.-P. Fryns, K. van der Steen, A. Kleczkowska, and J. Lauweryns, "The pathology of trisomy 13 syndrome. A study of 12 cases," *Human Genetics*, vol. 80, no. 4, pp. 349–356, 1988.
- [13] H.-Y. Lin, S.-P. Lin, Y.-J. Chen et al., "Clinical characteristics and survival of trisomy 13 in a medical center in Taiwan, 1985–," *Pediatrics International*, vol. 49, no. 3, pp. 380–386, 2007.
- [14] C. Quelin, E. Spaggiari, S. Khung-Savatovsky et al., "Inversion duplication deletions involving the long arm of chromosome 13: Phenotypic description of additional three fetuses and genotype-phenotype correlation," *The American Journal of Medical Genetics A*, 2014.
- [15] J. G. R. Kromberg and T. Jenkins, "Common birth defects in South African Blacks," *South African Medical Journal*, vol. 62, no. 17, pp. 599–602, 1982.
- [16] M. A. Sengeyi, K. Tshibangu, R. Tozin et al., "Etiopathogenesis and type of congenital malformations observed in Kinshasa (Zaire)," *Journal de Gynecologie Obstetrique et Biologie de la Reproduction*, vol. 19, no. 8, pp. 955–961, 1990.
- [17] A. B. Scott Emuakpor and E. D. N. Madueke, "The study of genetic variation in Nigeria, II: the genetics of polydactyly," *Human Heredity*, vol. 26, no. 3, pp. 198–202, 1976.
- [18] H. Goldstein and K. G. Nielsen, "Rates and survival of individuals with trisomy 13 and 18. Data from a 10-year period in Denmark," *Clinical Genetics*, vol. 34, no. 6, pp. 366–372, 1988.
- [19] J. P. Wyllie, M. J. Wright, J. Burn, and S. Hunter, "Natural history of trisomy 13," *Archives of Disease in Childhood*, vol. 71, no. 4, pp. 343–345, 1994.
- [20] H.-F. Hsu and J.-W. Hou, "Variable expressivity in Patau syndrome is not all related to trisomy 13 mosaicism," *The American Journal of Medical Genetics A*, vol. 143, no. 15, pp. 1739–1748, 2007.
- [21] Y. Tunca, J. S. Kadandale, and E. K. Pivnick, "Long-term survival in Patau syndrome," *Clinical Dysmorphology*, vol. 10, no. 2, pp. 149–150, 2001.
- [22] B. Zoll, J. Wolf, D. Lensing-Hebben, M. Pruggmayer, and B. Thorpe, "Trisomy 13 (Patau syndrome) with an 11-year survival," *Clinical Genetics*, vol. 43, no. 1, pp. 46–50, 1993.

- [23] A. Lumaka, G. Mubungu, C. Nsibu, B. P. Tady, T. Lukusa, and K. Devriendt, "X-linked adrenal hypoplasia congenita: a novel DAX1 missense mutation and challenges for clinical diagnosis in Africa," *European Journal of Pediatrics*, vol. 171, no. 2, pp. 267–270, 2012.
- [24] C. Haihambo and E. Lightfoot, "Cultural beliefs regarding people with disabilities in Namibia: implications for the inclusion of people with disabilities," *International Journal of Special Education*, vol. 25, no. 3, pp. 76–87, 2010.



**Hindawi**  
Submit your manuscripts at  
<http://www.hindawi.com>

