

Case Report

Novel *EPG5* Mutation Associated with Vici Syndrome Gene

Frouzandeh Mahjoubi ^{1,2}, Samira Shabani ^{1,3}, Sogand Khakbazzpour,³
and Aylar Khaligh Akhlaghi³

¹Department of Clinical Genetic, National Institute of Genetic Engineering and Biotechnology (NIGEB), Tehran, Iran

²Solaleh Medical Genetic Lan, Tehran, Iran

³The Islamic Azad University, Shahr-e-Qods Branch, Tehran, Iran

Correspondence should be addressed to Frouzandeh Mahjoubi; frouz@nigeb.ac.ir and Samira Shabani; shabani@nigeb.ac.ir

Received 23 November 2021; Revised 21 April 2022; Accepted 20 May 2022; Published 5 July 2022

Academic Editor: Balraj Mittal

Copyright © 2022 Frouzandeh Mahjoubi et al. This is an open access article distributed under the Creative Commons Attribution License, which permits unrestricted use, distribution, and reproduction in any medium, provided the original work is properly cited.

Introduction. Vici syndrome (also known as immunodeficiency with cleft lip/palate, cataract, and hypopigmentation and absent corpus callosum) is considered as a progressive neurodevelopmental multisystem disorder. Till date, only 80 cases, including our patient, with this syndrome have been reported. This syndrome is characterized by agenesis of the corpus callosum, hypopigmentation of the eyes and hair, cataract, cardiomyopathy, combined immunodeficiency, hearing loss, seizures, and additional multisystem involvements which have been reported as case reports in the past. **Clinical Manifestation.** A 5-year-old girl, who is a product of consanguineous marriage, was referred to our center with developmental delay, optic atrophy, blindness, spasticity, seizure, movement disability, and spasticity. Her magnetic resonance imaging (MRI) test showed agenesis of the corpus callosum and her metabolic test reported normal. **Materials and Methods.** In our laboratory, blood sample was obtained from the patient. DNA was extracted from lymphocytes, and whole exome sequencing (WES) using next generation Illumina sequencing was performed. **Result.** A novel (private), homozygous, nonsynonymous mutation c.A3206G (p.Y1069C Het) in *EPG5* gene was detected; in continuum, testing for this specific variant in her parents was carried out. DNA sequencing of the PCR-amplified product of the *EPG5* exon 17 showed that her parents were heterozygote for this variant. These mutations have not been reported before and therefore classified as variation of unknown significance (VUS). Mutation in this gene is shown to cause autosomal recessive Vici syndrome. **Conclusion.** Since clinical features of Vici syndrome has overlap, its diagnosis is differential and developmental delay occurs in 98% of reported cases. Vici syndrome can be considered as one of the main causes of developmental delay, and this syndrome can be introduced as a novel group of inherited neurometabolic conditions and congenital disorders.

1. Introduction

Vici syndrome (also known as immunodeficiency with cleft lip/palate, cataract, and hypopigmentation and absent corpus callosum, Dionisi Vici Sabetta Gambarara syndrome) is considered as a progressive neurodevelopmental multisystem disorder [1]. This syndrome is characterized by agenesis of the corpus callosum, hypopigmentation of the eyes and hair, cataracts, cardiomyopathy, combined immunodeficiency, hearing loss, seizures and additional multisystem involvements which have been reported as case reports in the past [2]. Vici syndrome is caused by recessive mutations in *EPG5* gene (OMIM #615068), which encodes one of the main regulators of the autophagy

pathway [2, 3]; therefore, it seems mutations in the *EPG5* gene underling the autophagy pathway by blocking the autophagosome-lysosome fusion mechanism [3]. Using the next generation technique, we introduce a 5-year-old girl as a new case of Vici syndrome with a new mutation in *EPG5* gene.

2. Case Report

A 5-year-old girl, who is a product of consanguineous marriage, was referred to our center with developmental delay, optic atrophy, blindness, seizure, movement disability, and spasticity. Her MRI test showed agenesis of the corpus callosum and her metabolic test reported normal (Figure 1).

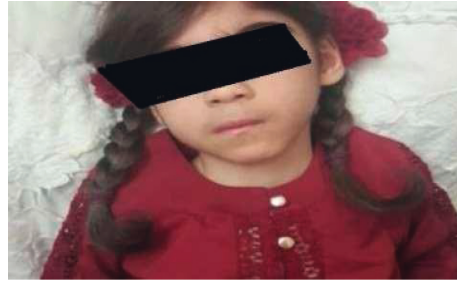

FIGURE 1: A 5-year-old girl with Vici syndrome.

TABLE 1: Two novels (private), homozygous, missense, and nonframeshift insertion mutations in *EPG5* gene detected by whole exome sequencing (WES) using next generation Illumina sequencing.

| Chr | Start | Ref | Alt | Gene | Zygoty | Function | Detail |
|-------|-----------|-----------|--------|-------------|-----------|------------------------|--|
| Chr18 | 45917712 | T | C | <i>EPG5</i> | Homo | Nonsynonymous | <i>EPG5</i> : NM-020964: exon17: c.A3206G: p.Y1069C |
| Chr18 | 45967193 | — | TGGCCT | <i>EPG5</i> | Homo | Nonframeshit insertion | <i>EPG5</i> : NM-020964: exon1: c.46-47insAGGCCA: p.S16delinsKAS |
| SIFT | PolyPhen2 | MutTaster | Pred | | BayanGene | 1000GenomeFreq | OMIM |
| 0.01 | 1 | 1 | D | CADD-Phred | 2 | . | Vici syndrome |
| . | 0 | . | . | . | 2 | 0.0 | Vici syndrome |

In our laboratory, blood sample was obtained from the patient. DNA was extracted from lymphocytes, and then, whole exome sequencing (WES) using next generation Illumina sequencing was performed. Two novel (private), homozygous, nonsynonymous mutations in *EPG5* gene were detected (Table 1). In continuum, testing for this specific variant in her parents was carried out. DNA sequencing of the PCR-amplified product of the *EPG5* exon 17 showed that her parents were heterozygote for this variant (Figure 2).

These mutations have not been reported before and therefore classified as variant of unknown significance (VUS). Mutation in this gene is shown to cause autosomal recessive Vici syndrome. Since the parents were found to be the carriers of the above mutation, the patient is very likely affected with Vici syndrome.

3. Discussion

Here, we describe an Iranian patient with Vici syndrome, born out of consanguineous marriage in a family from Persian descent. We report a novel homozygous, nonsynonymous mutation c.A3206G (p.Y1069C Het) in *EPG5* gene. This case had developmental delay, optic atrophy, blindness, spasticity, seizure, movement disability, and spasticity. Her MRI test showed agenesis of the corpus callosum and her metabolic test reported normal.

Vici syndrome was first report in 1988 by Carlo Dionisi-Vici et al. (Rome, Italy) [7, 8, 10]. Since then, only a few articles in the literature were reported with the name of Vici syndrome [2]. Subsequently, only about 80 people including our patient were reported with this disease up to date 5–9. This syndrome in most of the reported cases was related with a number of typical features including agenesis of the corpus callosum (97.4%), developmental delay (97.4%), recurrent

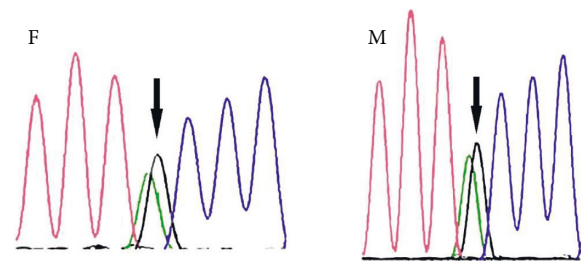


FIGURE 2: Heterozygous mutation c.A3206G (p.Y1069C; Het) on *EPG5* gene has been detected in father (F) and in mother (M) of this case (5-year-old girl) by DNA sequencing of the PCR-amplified product of the *EPG5* exon 17. Therefore, her parents are the carrier of this mutation. Since the parent found to be the carrier of the above mutation, the patient is very likely affected with Vici syndrome. Heterozygous mutation c.A3206G (p.Y1069C; Het) on *EPG5* gene has been detected in the 5-year-old girl.

infections (98.73%), immunodeficiency (75.94%), cardiomyopathy (65%), abnormal EEG (80–99% patients), intellectual disability (80–99% patients), cataracts (75%), seizures (65%), and renal abnormalities (15%) [6–11]. The clinical diagnostic method for Vici syndrome comprised of MRI of the brain, ophthalmic examination, EEG, cardiac ECHO, and sequencing of *EPG5* to confirm the diagnosis (https://www.malacards.org/card/vici_syndrome).

In 2013, it was reported that mutations in *EPG5* have been associated with Vici syndrome [6–11]. Ectopic P granules protein 5 homolog (*EPG5*, OMIM # 615068) is involved in the autophagy pathway and encodes one of the important regulators of this pathway. Autophagy is a highly conserved cellular degradative process which is involved in removal of organelles and defective proteins, and it is essential for removing waste products and reducing cell consumption [12].

EPG5 gene contains 47 exons, located on chromosome 18q21.1, has a length of 11967Kb (NC_000018.10), and coding 2579 amino acids (NP_066015.2) with a molecular weight of 280kDa [7]. *EPG5* encodes a large coiled coil domain-containing protein involved in the formation of lysosomes and functions in autophagy during starvation conditions (<https://www.ncbi.nlm.nih.gov/gene/57724#gene-expression>). It appears as mutations in *EPG5* gene blocks the autophagosome-lysosome fusion mechanism [3]. This gene has 1 isoform, and its protein expresses in most tissues, especially the bone marrow and thyroid tissues (<https://www.ncbi.nlm.nih.gov/gene/57724#gene-expression>).

Nearly 42 *EPG5* mutations have been reported to date for this syndrome, the majority of them truncating and private to distinct families [13]. Thomas et al. in 2013 carried out exome and Sanger sequence analysis in some affected Vici syndrome patients, and they found that recessive mutations in *EPG5* was associated with this disorder [6]. Since then, different mutations of *EPG5* gene were reported in which most of them are private [14].

There is no specific treatment for this syndrome yet and therapeutic interventions are more supportive to increase survival and relieve symptoms, but we hope a better understanding of the autophagy pathway will help the improvement of targeted therapies in future.

4. Conclusion

At first, the case features were suspected for metabolic disorders which were excluded since all of them were negative for this girl. While Vici syndrome is related with many different symptoms in metabolic diseases and congenital defects, we recommend that this syndrome should be investigated for in any case with agenesis of the corpus callosum if mitochondrial, glycogen, or lysosomal storage disorders have been excluded.

Conflicts of Interest

The authors declare that there are no conflicts of interest.

References

- [1] T. Chiyonobu, T. Yoshihara, Y. Fukushima et al., "Sister and brother with vici syndrome: agenesis of the corpus callosum, albinism, and recurrent infections," *American Journal of Medical Genetics*, vol. 109, no. 1, pp. 61–66, 2002.
- [2] M. Del Campo, B. D. Hall, A. Aeby et al., "Albinism and agenesis of the corpus callosum with profound developmental delay: vici syndrome, evidence for autosomal recessive inheritance," *American Journal of Medical Genetics*, vol. 85, no. 5, pp. 479–485, 1999.
- [3] T. Nagase, R. Kikuno, M. Nakayama, M. Hirosawa, and O. Ohara, "Prediction of the coding sequences of unidentified human genes. XVIII. The complete sequences of 100 new cDNA clones from brain which code for large proteins in vitro," *DNA Research*, vol. 7, no. 4, pp. 271–281, 2000.
- [4] C. Maillard, M. Cavallin, K. Piquand et al., "Prenatal and postnatal presentations of corpus callosum agenesis with

- polymicrogyria caused by *EPG5* mutation," *American Journal of Medical Genetics, Part A*, vol. 173, no. 3, pp. 706–711, 2017.
- [5] I. Hori, T. Otomo, M. Nakashima et al., "Defects in autophagosome-lysosome fusion underlie vici syndrome, a neurodevelopmental disorder with multisystem involvement," *Scientific Reports*, vol. 7, no. 1, p. 3552, 2017.
- [6] C. D. Vici, G. Sabetta, M. Gambarara et al., "Agenesis of the corpus callosum, combined immunodeficiency, bilateral cataract, and hypopigmentation in two brothers," *American Journal of Medical Genetics*, vol. 29, no. 1, pp. 1–8, 1988.
- [7] K. T. Abidi, N. M. Kamal, A. A. Bakkar et al., "Vici syndrome with pathogenic homozygous *EPG5* gene mutation: a case report and literature review," *Medicine*, vol. 99, no. 43, Article ID e22302, 2020.
- [8] T. Cullup, A. L. Kho, C. Dionisi-Vici et al., "Recessive mutations in *EPG5* cause Vici syndrome, a multisystem disorder with defective autophagy," *Nature genetics*, vol. 45, no. 1, pp. 83–87, 2013.
- [9] S. Byrne, L. Jansen, J. M. U-King-Im et al., "*EPG5*-related vici syndrome: a paradigm of neurodevelopmental disorders with defective autophagy," *Brain*, vol. 139, no. 3, pp. 765–781, 2016.
- [10] S. Byrne, C. Dionisi-Vici, L. Smith, M. Gautel, and H. Jungbluth, "Vici syndrome: a review," *Orphanet Journal of Rare Diseases*, vol. 11, no. 1, p. 21, 2016.
- [11] N. Ehmke, N. Parvaneh, P. Krawitz et al., "First description of a patient with vici syndrome due to a mutation affecting the penultimate exon of *EPG5* and review of the literature," *American Journal of Medical Genetics, Part A*, vol. 164, no. 12, pp. 3170–3175, 2014.
- [12] C. Hedberg-Oldfors, N. Darin, and S. Oldfors, "Muscle pathology in Vici syndrome-A case study with a novel mutation in *EPG5* and a summary of the literature," *Neuromuscular Disorders*, vol. 27, no. 8, pp. 771–776, 2017.
- [13] S. Tasdemir, A. Sahin, A. Cayir, I. Yuce, S. Ceylaner, and A. Tatar, "Tatar, Vici syndrome in siblings born to consanguineous parents," *American Journal of Medical Genetics Part A* 2016. 170(1);, pp. 220–225.
- [14] M. Spitzwieser, E. Holzweber, G. Pfeiler, G. Pfeiler, S. Hacker, and M. Cichna-Markl, "Applicability of HIN-1, MGMT and RASSF1A promoter methylation as biomarkers for detecting field cancerization in breast cancer," *Breast Cancer Research*, vol. 17, no. 1, pp. 1–13, 2015.