

Case Report

Colonic Angiosarcoma Arising in Association with Amyloid Deposits

Samar Said , Rondell P. Graham, Tsung-Teh Wu, Saba Yasir, Lizhi Zhang, and Andrew L. Folpe

Department of Laboratory Medicine and Pathology, Mayo Clinic, Rochester, MN, USA

Correspondence should be addressed to Samar Said; said.samar@mayo.edu

Received 5 December 2019; Revised 29 April 2020; Accepted 2 May 2020; Published 16 May 2020

Academic Editor: Chia-Tung Shun

Copyright © 2020 Samar Said et al. This is an open access article distributed under the Creative Commons Attribution License, which permits unrestricted use, distribution, and reproduction in any medium, provided the original work is properly cited.

Angiosarcoma of the colon is rare, as is colonic amyloidosis. To our knowledge, there have been no reported cases of angiosarcoma arising in association with amyloid deposition. Herein, we described a case of 77-year-old man who presented with hematochezia, and a sigmoid mass was found on colonoscopy. Histologic examination of the resected specimen showed extensive nodular deposition of AL-lambda amyloid material in the colonic wall, as well as high-grade angiosarcoma which was closely intermingled with the amyloid deposits. While the occurrence of both colonic amyloidosis and angiosarcoma in this patient may represent pure coincidence, given the intimate association of the angiosarcoma and the amyloid deposition and the rarity of both of these lesions, we hypothesize that angiosarcoma could be secondary to amyloid deposition.

1. Introduction

Angiosarcoma is a rare malignant vascular neoplasm that involves mainly skin and superficial soft tissue and is extremely rare in the gastrointestinal tract. Most sporadic cutaneous angiosarcomas arise in the setting of significant sun damage and are thought to be related to long-term UV radiation damage [1]. Another important subset of cutaneous angiosarcomas arises following therapeutic radiation or lymphedema, most often in the setting of breast carcinoma [2]. A small number of angiosarcomas have been reported to arise in association with foreign materials, including shrapnel, Dacron vascular grafts, orthopedic prosthetic hardware, and tophaceous gout. Colonic amyloidosis is also rare, and most cases are immunoglobulin light chain-related. It is well known that some types of amyloidosis can be caused by malignancies. For example, calcitonin type amyloid deposits are caused by medullary thyroid carcinoma, and immunoglobulin type amyloidosis can be secondary to plasma cell dyscrasia or lymphoma. The association between sarcoma and amyloidosis was described in only few case reports. However, to our knowledge, there are no reported cases of angiosarcoma arising in association

with amyloid deposition. Herein, we report an extremely rare example of colonic angiosarcoma arising in association with nodular amyloid deposits.

2. Case Presentation

A 77-year-old man with history of dementia, chronic kidney disease, gout, malignant melanoma of the skin, osteoarthritis, and gastroesophageal reflux disease presented with hematochezia. A nearly completely obstructing mass lesion in the sigmoid colon was found on colonoscopy. Follow-up staging CT scan of chest, abdomen, and pelvis showed a discrete mass in the distal sigmoid colon measuring approximately 10 cm in length, severe colonic wall thickening involving the distal colon and extending through the rectum, and a 2.5 cm right upper pole renal mass with heterogeneous enhancement worrisome for renal cell carcinoma. The patient underwent open sigmoidectomy. Grossly, there was a 3.4 × 2.0 × 0.5 cm ulcerated mass with raised borders. Sections submitted from the mass demonstrated extensive deposition of amorphous, pale eosinophilic material involving the lamina propria, muscularis mucosa, submucosa, muscularis propria, and subserosa with prominent

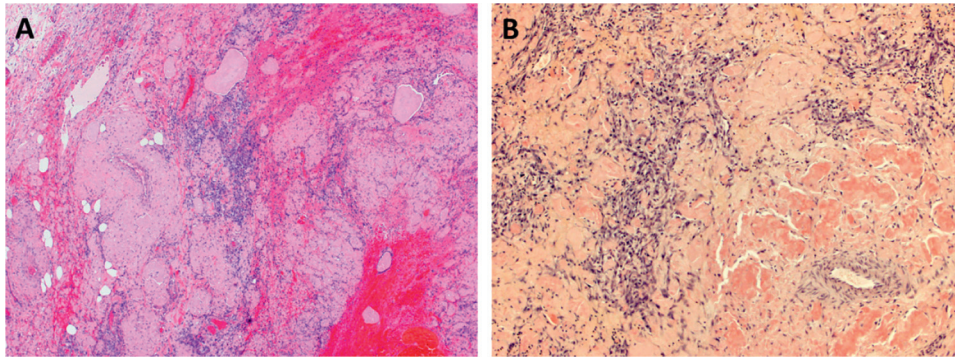


FIGURE 1: (a) Representative low-power image showing sheets of malignant cells and hemorrhage present between areas of extensive amyloid deposition ($\times 40$). (b) The amyloid deposits are Congo-Red positive ($\times 100$).

involvement of vessels (Figure 1(a)). The material was positive with a Congo red stain (Figure 1(b)) and showed apple-green birefringence under polarized light, characteristic of amyloid. Closely intermingled with and diffusely infiltrating the amyloid deposits, there were sheets of highly atypical, plump spindled cells with amphophilic cytoplasm, oval large nuclei, prominent nucleoli, and frequent mitotic figures (Figures 2(a) and 2(b)). Intracytoplasmic vacuoles containing red blood cells were identified in some of the tumor cells. There were also areas of hemorrhage and blood lakes. The tumor cells were positive for endothelial markers including CD31 (patchy), ERG, and FLI1, confirming the diagnosis of angiosarcoma (Figures 2(c) and 2(d)) and negative for keratins (AE1/AE3), SOX10, S100 protein, and KIT (Figures 3(a)–3(d)). Strong expression of MYC protein by immunohistochemistry was present (Figure 2(e)). Fluorescence in situ hybridization (FISH) showed no evidence of MYC gene amplification.

Amyloid typing by laser microdissection (LMD) followed by high-performance liquid chromatography and tandem mass spectrometry (LC-MS/MS) confirmed the presence of amyloid and was consistent with AL (λ)-type. No infiltration of plasma cells in the vicinity of amyloid deposits was seen. Due to the patient's advanced dementia, the family decided not to pursue aggressive therapy and opted for palliative care.

3. Discussion

Angiosarcoma is a rare malignant vascular neoplasm that involves mainly skin and superficial soft tissue but may occur in large vessels, deep soft tissue, and parenchymal organs such as the liver, spleen, bone, breast, and heart. It can be primary or secondary. Long-term sun exposure, radiation, chronic lymphedema, and exposure to Thorotrast, polyvinylchloride, and arsenic are known risk factors [1–5]. Angiosarcoma has also reported in association with arteriovenous fistulas in patients with renal failure [6–12], arthroplasty [13, 14], and injection sites [15] and in association with foreign materials that can be introduced to the body during trauma, surgery, and injection or formed in situ. Foreign materials reported to cause angiosarcoma include metals (such as bullets, shrapnel, cardiac defibrillator

implants, and orthopedic joint prostheses) [16–20], Dacron graft [18, 21], silicone breast implants [22–24], retained surgical material such as sponge [25–27], and a gouty tophus (where it was hypothesized that the angiosarcoma was induced by the gouty tophus in a mechanism similar to that of foreign body-associated sarcoma) [28]. While development of sarcoma in association with foreign material occurs only rarely in humans, it is a well-documented phenomenon in rodents in which investigators have demonstrated the development of sarcoma after insertion of foreign material [29]. Different types of sarcoma have been reported in this setting including undifferentiated sarcoma, angiosarcoma, osteosarcoma, and chondrosarcoma. There is usually a prolonged latency period between the initial exposure to the foreign material and development of sarcoma [30]. The physical properties of the material seem to play a role in tumorigenesis, as the tumorigenic effect is reduced or lost when the foreign materials are inserted in pulverized or shredded forms, when their surface is rough or when they contain large pores. Formation of thick fibrous capsule around the foreign material is thought to play a role in tumorigenesis as tumorigenic material developed more fibrosis than the nontumorigenic material [30, 31]. MYC amplification, and strong MYC protein expression, initially thought to be limited to secondary angiosarcoma (such as postradiation and lymphedema-associated angiosarcoma) [32], is now known to occur in primary angiosarcoma as well [33].

Colonic angiosarcoma is extremely rare. Wang et al. reported a case of colonic angiosarcoma and summarized the results of 33 previously reported cases [34]. The mean age was 56 years (range 16 to 85 years), and the mean tumor size was 5 cm (range 1.5–12 cm). In more than two thirds of the cases, the tumor was in the left colon (36% in the sigmoid colon and 33% in the anorectal region), whereas 21% were in the cecum, 9% in the ascending colon, and 3% in the transverse and descending colon. Four of the 33 patients had a history of radiation exposure, and in one patient the tumor was associated with retained surgical gauze. An association with renal transplantation, long-term hemodialysis, and chronic colorectal ulcers were also reported (one case each). Clinical symptoms included gastrointestinal bleeding (67%), abdominal/anal pain (46%), intestinal obstruction (24%),

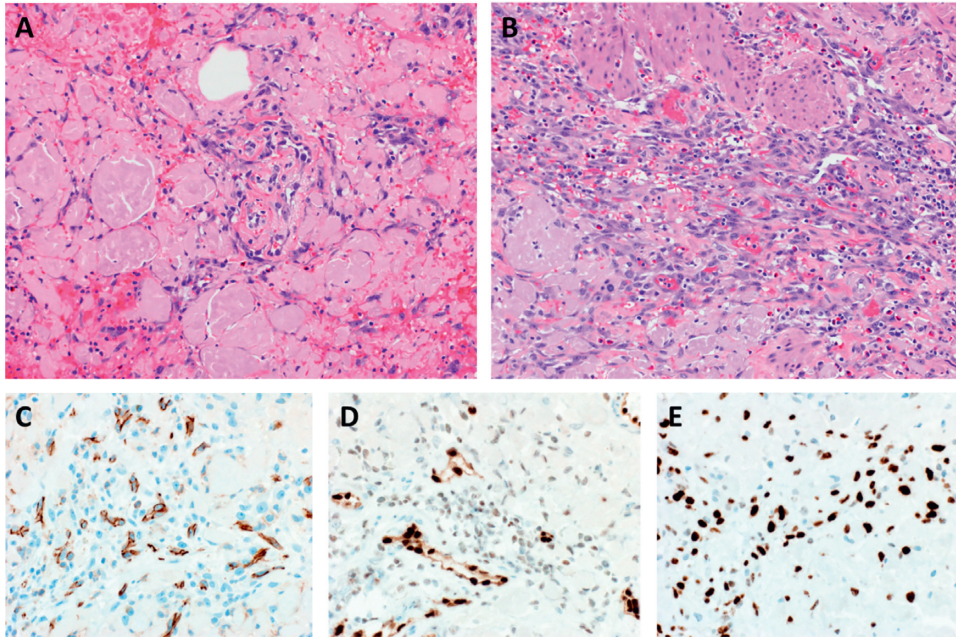


FIGURE 2: (a, b) Diffuse infiltration of amyloid deposits by high-grade angiosarcoma ($\times 200$). (c–e) The malignant cells are positive for CD31 (patchy) (c), ERG (d), and MYC (e) ($\times 400$).

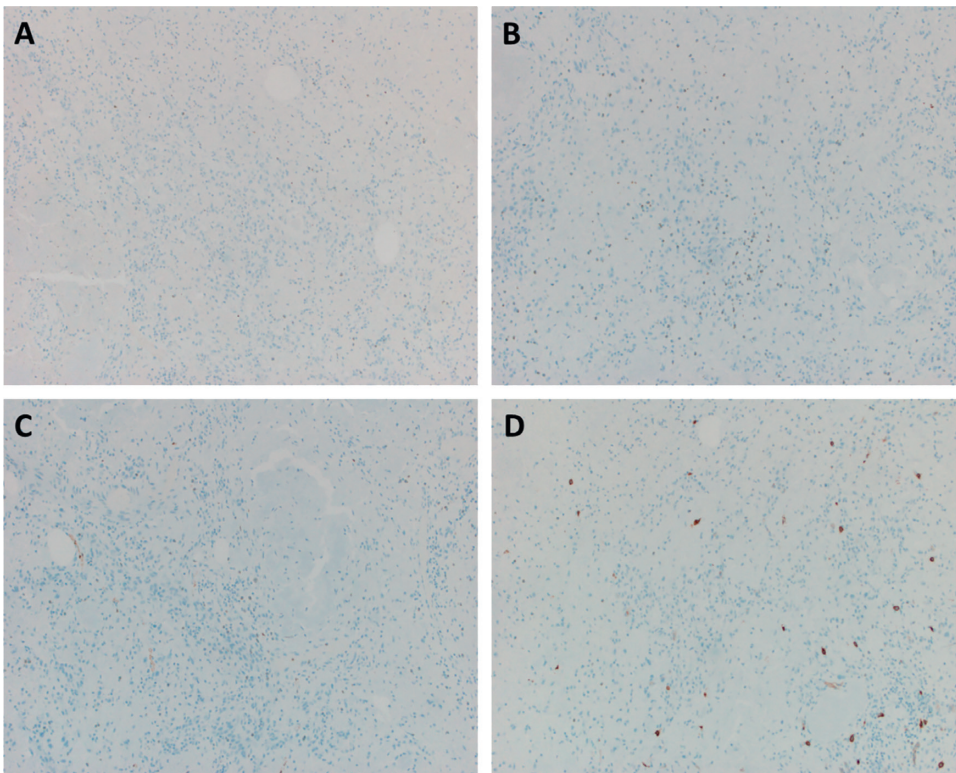


FIGURE 3: (a–d) The tumor cells are negative for keratin AE1/AE3 (a), SOX10 (b), S100 (c), and KIT (d) ($\times 100$).

diarrhea (50%), and weight loss (18%). Anemia was present in 42% of patients. Prognosis was poor with a median survival of 4.5 months. Tumor size less than 5 cm and younger age were associated with better prognosis. In general, colonic angiosarcomas are treated surgically,

although there may also be a role for adjuvant therapies, including radiation, chemotherapy, and immunotherapy. Gastrointestinal amyloidosis is also rare. Cowan et al. [35] reported 76 patients with gastrointestinal amyloidosis (accounted for 3.2% of patients with amyloidosis), most of

which (80%) were due to immunoglobulin light chain. The median age was 61 years (range 34 to 79 years). The stomach was the most affected site involved in 49% of cases followed by the colorectal region (46%), small bowel (42%), and esophagus (8%). Clinical symptoms included weight loss (43%), gastrointestinal bleeding (37%), heartburn (33%), early satiety (33%), diarrhea (29%), and abdominal pain (28%). The amyloidosis was systemic in 79% of cases and localized (i.e., without evidence of an underlying plasma cell dyscrasia or other organ involvement) in 21%. Supportive care was the main treatment for localized gastrointestinal amyloidosis with all patients alive at a median follow-up of 36 months. Patients with systemic AL amyloidosis were treated with anti-plasma cell chemotherapy with 72% survival rate at 4 years.

Amyloid has multiple precursor proteins and can occur in different settings including chronic inflammatory conditions, certain neoplasms, genetic/inherited, and age-related. Hematologic malignancies and medullary thyroid carcinoma are two neoplasms that are known to cause amyloid deposition where medullary thyroid carcinoma causes calcitonin type amyloid and plasma cell dyscrasia and some types of lymphoma can cause immunoglobulin related amyloidosis [36]. Amyloid deposition has also been reported in association with other epithelial neoplasms including urothelial carcinoma, neuroendocrine tumors, pituitary adenoma, gastric carcinoma, nasopharyngeal carcinoma, breast carcinoma, and endometrioid carcinoma and rarely in association with sarcomas including Kaposi's sarcoma, follicular dendritic cell sarcoma, leiomyosarcoma, and pleomorphic sarcoma [37–56]. The relationship between the amyloid and most of the previously mentioned neoplasms, however, is largely unknown. To our knowledge, this is the first case of angiosarcoma arising in association with amyloid deposition. This may represent a purely coincidental occurrence. However, given the intimate association of the angiosarcoma and the amyloid deposition and the rarity of both colonic angiosarcoma and colonic amyloidosis, angiosarcoma could be secondary to the amyloid deposition. It is unlikely that the amyloidosis was secondary to the angiosarcoma, as the area of amyloid deposition was considerably larger than the area involved by angiosarcoma, angiosarcoma was present only within areas of the colon also involved by amyloid, and amyloid deposition has never been previously reported in association with this tumor type. Furthermore, angiosarcomas are rapidly growing, aggressive tumors that usually come quickly to clinical attention. Perhaps most importantly, the amyloidosis type was AL (lambda)-type, which is not known to arise from solid malignancies but rather results from production of amyloidogenic light chains from a clonal plasma cell population. Other factors such as chronic illness or genetic predisposition might have contributed to this exceptional occurrence. AL amyloidosis is the most common type of both systemic and localized amyloidosis. In localized AL amyloidosis, the amyloidogenic light chain is thought to arise from local plasma cell populations, but histologic evidence of monoclonal plasma cell infiltration or lymphoma adjacent to amyloid deposits is not always present [57] (as in this case).

Unfortunately, the patient's family decided against further workup, and thus we do not know if his amyloidosis was systemic or localized.

In summary, we report an extremely rare occurrence of a high-grade colonic angiosarcoma arising in close association with colonic amyloidosis. Although the exact relationship between the tumor and amyloid is obscure, it is tempting to speculate that the amyloid deposits may have served as the inciting tumorigenic event, although pure coincident cannot be completely excluded.

Conflicts of Interest

The authors declare that they have no conflicts of interest.

References

- [1] E. Shustef, V. Kazlouskaya, V. G. Prieto, D. Ivan, and P. P. Aung, "Cutaneous angiosarcoma: a current update," *Journal of Clinical Pathology*, vol. 70, no. 11, pp. 917–925, 2017.
- [2] M. Co, A. Lee, and A. Kwong, "Cutaneous angiosarcoma secondary to lymphoedema or radiation therapy - a systematic review," *Clinical Oncology*, vol. 31, no. 4, pp. 225–231, 2019.
- [3] G. S. Lipshutz, T. V. Brennan, and R. S. Warren, "Thorotrast-induced liver neoplasia: a collective review," *Journal of the American College of Surgeons*, vol. 195, no. 5, pp. 713–718, 2002.
- [4] K. A. Mundt, L. D. Dell, L. Crawford, and A. E. Gallagher, "Quantitative estimated exposure to vinyl chloride and risk of angiosarcoma of the liver and hepatocellular cancer in the US industry-wide vinyl chloride cohort: mortality update through 2013," *Occupational and Environmental Medicine*, vol. 74, no. 10, pp. 709–716, 2017.
- [5] M. Salgado, M. Sans, X. Fornas et al., "Hepatic angiosarcoma: a report of a case associated with treatment with arsenic salts and a review of the literature," *Gastroenterol Hepatology*, vol. 18, no. 3, pp. 132–135, 1995.
- [6] J. D. Kakisis, C. Antonopoulos, K. Moulakakis et al., "Angiosarcoma of a thrombosed arteriovenous fistula in a renal transplant recipient," *Annals of Vascular Surgery*, vol. 56, pp. e1–e4, 2019.
- [7] D. Heining, J. Senior, A. Prasad, M. Thomas, A. Bentall, and P. J. Yates, "Multi-system bleeding risk with a cutaneous angiosarcoma at an arteriovenous fistula site," *Oxford Medical Case Reports*, vol. 2018, no. 10, Article ID omy063, 2018.
- [8] S. F. Roy, F. M. Ghazawi, A. Alsarheed, K. D. Lach, K. Watters, and E. O'Brien, "Angiosarcoma arising within a nonfunctioning arteriovenous fistula," *International Journal of Dermatology*, vol. 57, no. 12, pp. 1513–1515, 2018.
- [9] B. N. L. Costa, C. F. Rivera, M. C. Rodriguez et al., "Angiosarcoma developing in an arteriovenous fistula after kidney transplantation," *Case Reports in Transplantation*, vol. 2017, Article ID 2426859, 3 pages, 2017.
- [10] R. A. Aldaabil, A. M. Alkhunaizi, N. A. Al-Dawsari, M. F. Dawamneh, and R. Rabah, "Angiosarcoma at the site of nonfunctioning arteriovenous fistula in a kidney transplant recipient," *Journal of Vascular Surgery Cases and Innovative Techniques*, vol. 2, no. 2, pp. 53–55, 2016.
- [11] Y. Oskrochi, K. Razi, J. Stebbing, and J. Crane, "Angiosarcoma and dialysis-related arteriovenous fistulae: a comprehensive review," *European Journal of Vascular and Endovascular Surgery*, vol. 51, no. 1, pp. 127–133, 2016.

- [12] A. L. Gale, R. A. W. Marco, S. R. Liberman, D. Zavlin, and A. Echo, "Case report: angiosarcoma in the upper extremity related to a nonfunctioning arteriovenous fistula," *Hand*, vol. 12, no. 5, pp. NP132–NP135, 2017.
- [13] S. Terrando, A. Sambri, G. Bianchi et al., "Angiosarcoma around total hip arthroplasty: case series and review of the literature," *Musculoskelet Surgery*, vol. 102, no. 1, pp. 21–27, 2018.
- [14] A. Mallick, S. Jain, A. Proctor, and R. Pandey, "Angiosarcoma around a revision total hip arthroplasty and review of literature," *Journal of Arthroplasty*, vol. 24, no. 2, pp. 323–20, 2009.
- [15] H. Cheng and P. W. Allen, "Selected case from the Arkadi M. Rywlin International Pathology Slide Seminar," *Advances in Anatomic Pathology*, vol. 18, no. 4, pp. 329–332, 2011.
- [16] T. Schneider, J. Renney, and J. Hayman, "Angiosarcoma occurring with chronic osteomyelitis and residual foreign material: case report of a late World War II wound complication," *ANZ Journal of Surgery*, vol. 67, no. 8, pp. 576–578, 1997.
- [17] J. Hayman and H. Huygens, "Angiosarcoma developing around a foreign body," *Journal of Clinical Pathology*, vol. 36, no. 5, pp. 515–518, 1983.
- [18] A. Agaimy, O. Ben-Izhak, T. Lorey, M. Scharpf, and B. P. Rubin, "Angiosarcoma arising in association with vascular Dacron grafts and orthopedic joint prostheses: clinicopathologic, immunohistochemical, and molecular study," *Annals of Diagnostic Pathology*, vol. 21, pp. 21–28, 2016.
- [19] S. C. Smith, K. D. Bernacki, J. W. Haft, and J. B. McHugh, "Internal cardiac defibrillator implant-associated angiosarcoma presenting as suspected implant pouch infection," *Cardiovascular Pathology*, vol. 22, no. 1, pp. 105–108, 2013.
- [20] D. J. McDonald, W. F. Enneking, and M. Sundaram, "Metal-associated angiosarcoma of bone: report of two cases and review of the literature," *Clinical Orthopaedics and Related Research*, vol. 396, pp. 206–214, 2002.
- [21] O. Ben-Izhak, E. Vlodavsky, A. Ofer, A. Engel, S. Nitecky, and A. Hoffman, "Epithelioid angiosarcoma associated with a Dacron vascular graft," *The American Journal of Surgical Pathology*, vol. 23, no. 11, pp. 1418–1422, 1999.
- [22] N. R. Smoll, R. D. Farhadieh, R. Ferguson, M. W. Findlay, and D. J. Hunter-Smith, "High-grade angiosarcoma associated with ruptured breast implants," *Plastic and Reconstructive Surgery Global Open*, vol. 1, no. 1, 2013.
- [23] M. Takenaka, M. Tanaka, M. Isobe, R. Yamaguchi, M. Kojiro, and K. Shirouzu, "Angiosarcoma of the breast with silicone granuloma: a case report," *The Kurume Medical Journal*, vol. 56, no. 1-2, pp. 33–37, 2009.
- [24] N. D. Saunders, J. S. Marshall, and R. C. Anderson, "A case of chest wall angiosarcoma associated with breast implants," *The Journal of Thoracic and Cardiovascular Surgery*, vol. 134, no. 4, pp. 1076–1077, 2007.
- [25] K. Cokelaere, J. Vanvuchelen, P. Michielsen, and R. Sciot, "Epithelioid angiosarcoma of the splenic capsule," *Virchows Archiv*, vol. 438, no. 4, pp. 398–403, 2001.
- [26] O. Ben-Izhak, H. Kerner, B. Brenner, and C. Lichtig, "Angiosarcoma of the colon developing in a capsule of a foreign body: report of a case with associated hemorrhagic diathesis," *American Journal of Clinical Pathology*, vol. 97, no. 3, pp. 416–420, 1992.
- [27] Y.-T. Joo, C.-Y. Jeong, E.-J. Jung et al., "Intra-abdominal angiosarcoma developing in a capsule of a foreign body: report of a case with associated hemorrhagic diathesis," *World Journal of Surgical Oncology*, vol. 3, no. 1, p. 60, 2005.
- [28] A. L. Folpe, C. A. Johnston, and S. W. Weiss, "Cutaneous angiosarcoma arising in a gouty tophus," *The American Journal of Dermatopathology*, vol. 22, no. 5, pp. 418–421, 2000.
- [29] K. G. Brand, K. H. Johnson, L. C. Buoan, and L. Golberg, "Foreign body tumorigenesis," *CRC Critical Reviews in Toxicology*, vol. 4, no. 4, pp. 353–394, 1976.
- [30] T. A. Jennings, L. Peterson, C. A. Axiotis, G. E. Friedlaender, R. A. Cooke, and J. Rosai, "Angiosarcoma associated with foreign body material: a report of three cases," *Cancer*, vol. 62, no. 11, pp. 2436–2444, 1988.
- [31] F. Bischoff and G. Bryson, "Carcinogenesis through solid state surfaces," *Progress in Experimental Tumor Research*, vol. 5, no. 5, pp. 85–133, 1964.
- [32] J. Manner, B. Radlwimmer, P. Hohenberger et al., "MYC high level gene amplification is a distinctive feature of angiosarcomas after irradiation or chronic lymphedema," *The American Journal of Pathology*, vol. 176, no. 1, pp. 34–39, 2010.
- [33] W. Shon, W. R. Sukov, S. M. Jenkins, and A. L. Folpe, "MYC amplification and overexpression in primary cutaneous angiosarcoma: a fluorescence in-situ hybridization and immunohistochemical study," *Modern Pathology*, vol. 27, no. 4, pp. 509–515, 2014.
- [34] Q. Wang, T. Zhao, B.-T. Mi et al., "Primary colonic angiosarcoma seen in a patient on calcium channel blocker: a case report with summary analysis of 32 other cases from the literature," *American Journal of Case Reports*, vol. 19, pp. 254–261, 2018.
- [35] A. J. Cowan, M. Skinner, D. C. Seldin et al., "Amyloidosis of the gastrointestinal tract: a 13-year, single-center, referral experience," *Haematologica*, vol. 98, no. 1, pp. 141–146, 2013.
- [36] E. D. Williams, C. L. Brown, and I. Doniach, "Pathological and clinical findings in a series of 67 cases of medullary carcinoma of the thyroid," *Journal of Clinical Pathology*, vol. 19, no. 2, pp. 103–113, 1966.
- [37] D. Sirohi, J. Gandhi, M. B. Amin, and D. J. Luthringer, "Amyloidosis of the bladder and association with urothelial carcinoma: report of 29 cases," *Human Pathology*, vol. 93, pp. 48–53, 2019.
- [38] R. R. Vanga, S. Dhingra, and K. Patel, "Insulin expressing pancreatic neuroendocrine tumor associated with intratumor amyloidosis," *Clinical Gastroenterology and Hepatology*, vol. 15, no. 10, pp. A35–A36, 2017.
- [39] S. O. Brannan, N. G. Lessan, P. Hiscott, and B. Damato, "A choroidal amyloid-rich neuroendocrine tumor," *Archives of Ophthalmology*, vol. 117, no. 8, pp. 1081–1083, 1999.
- [40] N. Al-Kaisi, F. W. Abdul-Karim, G. Mendelsohn, and G. Jacobs, "Bronchial carcinoid tumor with amyloid stroma," *Archives of Pathology & Laboratory Medicine*, vol. 112, no. 2, pp. 211–214, 1988.
- [41] S. Faruqi, K. Gumparthy, and Z. Wahbi, "Elevated CA 19-9 levels observed in association with a pulmonary neuroendocrine tumour and amyloid," *Internal Medicine*, vol. 52, no. 1, pp. 105–109, 2013.
- [42] A. Samad, R. Attam, J. Jessurun, and S. E. Pambuccian, "Psammoma bodies and abundant stromal amyloid in an endoscopic ultrasound guided fine needle aspirate (EUS-FNA) of a pancreatic neuroendocrine tumor: a potential pitfall," *Diagnostic Cytopathology*, vol. 42, no. 9, pp. 766–771, 2014.
- [43] M. Shintaku, H. Tado, K. Inayama, T. Murakami, and T. Suzuki, "Ductulo-insular pancreatic endocrine tumor with amyloid deposition: report of a case," *Pathology International*, vol. 65, no. 4, pp. 197–201, 2015.

- [44] S. N. Levine, S. Ishaq, A. Nanda, J. D. Wilson, and E. Gonzalez-Toledo, "Occurrence of extensive spherical amyloid deposits in a prolactin-secreting pituitary macroadenoma: a radiologic-pathologic correlation," *Annals of Diagnostic Pathology*, vol. 17, no. 4, pp. 361–366, 2013.
- [45] C. O. Sung, Y.-L. Suh, and D. K. Lee, "Extensive spherical amyloid deposition of pituitary adenoma presenting as pituitary apoplexy," *Clinical Neurology and Neurosurgery*, vol. 110, no. 4, pp. 424–425, 2008.
- [46] T. Iwase, S. Nishizawa, S. Baba et al., "Intrasellar neuronal choristoma associated with growth hormone-producing pituitary adenoma containing amyloid deposits," *Human Pathology*, vol. 26, no. 8, pp. 925–928, 1995.
- [47] K. Aoyagi, K. Koufujii, S. Yano et al., "Early gastric carcinoma associated with amyloidosis: a case report," *The Kurume Medical Journal*, vol. 49, no. 3, pp. 153–156, 2002.
- [48] M. Munichor, H. Cohen, H. Kerner, S. Szvalb, and T. C. Iancu, "Localized amyloidosis in nasopharyngeal carcinoma diagnosed by fine needle aspiration and electron microscopy," *Acta Cytologica*, vol. 44, no. 4, pp. 673–678, 2000.
- [49] J. M. Sabate, M. Clotet, S. Torrubia et al., "Localized amyloidosis of the breast associated with invasive lobular carcinoma," *The British Journal of Radiology*, vol. 81, no. 970, pp. e252–e254, 2008.
- [50] M. Kotru, H. Chandra, N. Singh, and A. Bhatia, "Localized amyloidosis in endometrioid carcinoma of the uterus: a rare association," *Archives of Gynecology and Obstetrics*, vol. 276, no. 4, pp. 383–384, 2007.
- [51] I. Agha, R. Mahoney, M. Beardslee, H. Liapis, R. G. Cowart, and I. Juknevicus, "Systemic amyloidosis associated with pleomorphic sarcoma of the spleen and remission of nephrotic syndrome after removal of the tumor," *American Journal of Kidney Diseases*, vol. 40, no. 2, pp. 411–415, 2002.
- [52] M. F. Chiaramonte, D. Lee, L. V. Abruzzo, M. Heyman, and B. L. Bass, "Retroperitoneal follicular dendritic cell sarcoma presenting as secondary amyloidosis," *Surgery*, vol. 130, no. 1, pp. 109–111, 2001.
- [53] S. Onishi, N. Hojo, I. Sakai et al., "Secondary amyloidosis and eosinophilia in a patient with uterine leiomyosarcoma," *Japanese Journal of Clinical Oncology*, vol. 35, no. 10, pp. 617–621, 2005.
- [54] M. I. Kudrina, E. A. Markina, V. V. Sura, and A. A. Vorob'eva, "Secondary amyloidosis in patient with Kaposi's sarcoma," *Ter Arkh*, vol. 71, no. 12, pp. 53–56, 1999.
- [55] D. S. Shimm, G. L. Logue, M. B. Rohlfing, and J. T. Gaede, "Primary amyloidosis, pure red cell aplasia, and Kaposi's sarcoma in a single patient," *Cancer*, vol. 44, no. 4, pp. 1501–1503, 1979.
- [56] J. Favreau, L. P. Legresley, and C. Beaudry, "Kaposi's sarcoma associated with primary amyloidosis, with chronic renal insufficiency," *Canadian Medical Association*, vol. 103, no. 8, pp. 1683–1687, 1973.
- [57] S. M. Said, C. Reynolds, R. E. Jimenez et al., "Amyloidosis of the breast: predominantly AL type and over half have concurrent breast hematologic disorders," *Modern Pathology*, vol. 26, no. 2, pp. 232–238, 2013.