

## Case Report

# Large Uterine Fibroids in Pregnancy with Successful Caesarean Myomectomy

Edu Eyong  and Okon A. Okon 

*Department of Obstetrics & Gynecology, Faculty of Medicine, University of Calabar, Calabar, Cross River State, Nigeria*

Correspondence should be addressed to Okon A. Okon; [konie9ja@gmail.com](mailto:konie9ja@gmail.com)

Received 30 June 2020; Revised 15 October 2020; Accepted 28 October 2020; Published 10 November 2020

Academic Editor: Mehmet A. Osmanağaoğlu

Copyright © 2020 Edu Eyong and Okon A. Okon. This is an open access article distributed under the Creative Commons Attribution License, which permits unrestricted use, distribution, and reproduction in any medium, provided the original work is properly cited.

Uterine fibroid is the commonest benign tumour of the female reproductive tract. It occurs in 20–40% of women, whereas the estimated incidence in pregnancy is 0.1–3.9%. Uterine fibroid in pregnancy is usually asymptomatic with complications occurring in 10–30% of cases. The first line of management is conservative with counselling for myomectomy after delivery. However, in the presence of intractable symptoms, both antepartum myomectomy and caesarean myomectomy have been reported to be successfully performed in carefully selected cases. We report a case of large subserous uterine fibroid in pregnancy that was referred to our centre at 14 weeks of gestation. She developed generalized body weakness, backache, and breathlessness at 27 weeks gestation. Thus, she was admitted and managed conservatively for eight weeks with significant relief of symptoms. She eventually had a caesarean myomectomy at 35 weeks of gestation; the outcome was a live female baby with a birth weight of 2.3 kg and a large subserous fibroid weighing 9.5 kg. We can therefore say that caesarean myomectomy can be safely performed in carefully selected cases.

## 1. Introduction

Uterine fibroids are the commonest benign tumours of the female reproductive tract which arise from the smooth muscle cells of the uterus [1, 2]. It is a common gynaecological tumour in Nigeria [3]. They could be single or multiple in number and present in varying sizes. They occur two to three times commoner in black women than in Caucasian women [1]. It occurs in 20–40% of women, whereas the estimated incidence in pregnancy is 0.1–3.9%. The much lower incidence in pregnancy could be explained by the fact that uterine fibroid is associated with infertility as well as low implantation rates after in vitro fertilization [4]. However, the incidence of uterine fibroids in pregnancy could be underestimated since most uterine fibroids are asymptomatic and a lot of women may not undergo routine ultrasound scan in pregnancy [5]. The first line of management of uterine fibroids coexisting with pregnancy is conservative with counselling for myomectomy after delivery. This is because they are usually asymptomatic with complications occurring in 10–30% of cases during pregnancy, labour, and/or puerpe-

rium [6, 7]. However, in the presence of intractable symptoms, some patients have been offered termination of pregnancy [8]. Alternatively, both antepartum myomectomy [8–10] and caesarean myomectomy [11–15] have been done successfully in carefully selected cases.

We decided to document this case of successful caesarean myomectomy done in our clinical setting of limited resources to encourage the broadening of counselling options in carefully selected cases.

## 2. Presentation of Case

A 37-year-old G3P0<sup>+1</sup> lady was referred from a secondary level facility to our centre due to a huge uterine fibroid coexisting with pregnancy at 14 weeks gestation.

She presented with a seven-year history of abdominal swelling and amenorrhoea of 14 weeks duration. The abdominal swelling was progressively increasing in size with associated abdominal pain of one-month duration. There was no history of vaginal bleeding, bowel/urinary, or other symptoms.

She did not seek any medical advice or treatment for the abdominal swelling before she became pregnant. Pregnancy was confirmed by an ultrasound scan at 12 weeks gestation.

On examination, the patient was not in respiratory distress, clinically pale, afebrile, anicteric, and no pedal oedema. The pulse rate was 88 beats per minute, and blood pressure was 90/50 mmHg. The respiratory rate was 18 cycles per minute. The abdomen was grossly distended and there was a huge, firm abdominopelvic mass measuring 44 cm from the symphysis pubis. Abdominopelvic sonography showed a viable singleton intrauterine foetus of 14 weeks gestation. It also showed a huge subserous uterine fibroid measuring about 25 cm × 18 cm at the left anterior aspect of the uterus. Blood tests showed a haematocrit of 28% and normal electrolytes and urea and creatinine levels. The woman's blood group was O Rhesus "D" positive, and the haemoglobin genotype was AA.

The patient was seen at two weekly intervals at the antenatal clinic. She was treated with haematinics, antihelminthics, and malaria chemoprophylaxis. She was successfully treated for malaria during this period (with oral artemisinin-combined therapy) when she had clinical symptoms and a positive smear test.

She was admitted into the antenatal ward at the gestational age of 27 weeks due to complaints of generalized body weakness, back pains, and breathlessness. She had a second episode of malaria while on admission which was again successfully treated with oral artemisinin-combined therapy. She was admitted for eight weeks and was conservatively managed with bed rest, hydration, analgesics and fetomaternal monitoring. The conservative management resulted in the significant relief of all the symptoms.

During the period of admission, the patient had a transfusion of one unit of packed cells. She also received intravenous iron dextran and subcutaneous erythropoietin to correct anaemia. At the end of treatment, the haematocrit was 35%.

She was counselled for an elective caesarean section while on admission to which she gave her consent. Intramuscular dexamethasone was administered preoperatively to aid foetal lung maturity.

Elective caesarean section was carried out under spinal anaesthesia at 35 weeks of gestation. Figure 1 shows the outline of the uterus and the uterine fibroid before the commencement of the operation, with the uterus deviated to the right flank and the fibroid located centrally. The abdomen was then opened by a midline subumbilical incision. The huge subserous uterine fibroid was located centrally with the uterus deviated to the right abdominal flank. The outcome was a live female infant of birth weight 2.3 kg and Apgar scores 5 and 8 at 1 and 5 minutes, respectively. Following the delivery of the baby, the uterine incision was repaired. The uterus was then exteriorized, and the relationship of the fibroid to the uterus is as shown in Figure 2. Thereafter, a Foley catheter size 18FG was applied as tourniquet at the level of the internal cervical os; intracapsular myomectomy was successfully performed with careful closure and good homeostasis ensured. The fibroid nodule as seen in Figure 3 showed areas of cystic degeneration and weighed 9.5 kg. It

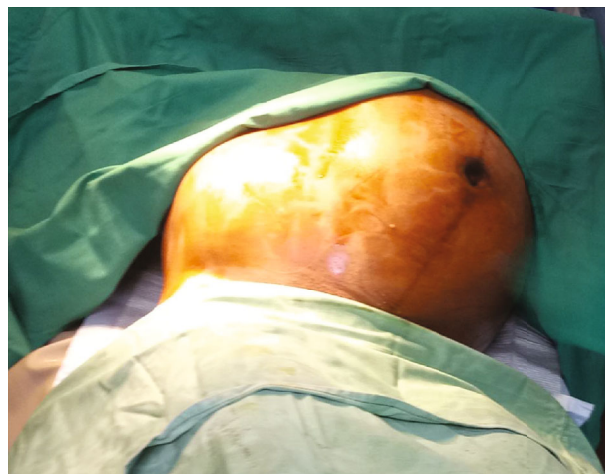

FIGURE 1: Outline of the uterus and the uterine fibroid before surgery.

was sent for histology, and the report later confirmed the diagnosis of a leiomyoma with areas of cystic degeneration and no evidence of malignancy. Estimated blood loss after surgery was 800 ml, and two units of whole blood were transfused postoperatively. She also received analgesics and antibiotics postoperatively. Postoperative haematocrit was 30%. She had an uneventful postoperative period and was discharged from the hospital after five days. The postnatal visit after six weeks was satisfactory.

### 3. Discussion

The incidence of uterine fibroids in pregnancy would likely increase globally due to delay in childbearing which is more prevalent now due to different factors [16–19]. In Nigeria, like other black nations, there is a higher tendency of the women to develop uterine fibroids due to several mechanisms [16, 20]. Also, our women usually present late for treatment due to poor health-seeking behaviour, sociocultural and financial constraints, and the fear of surgery [16, 21, 22]. This delay in presentation for treatment makes our black women more likely to present with large and/or multiple uterine fibroids which have a higher risk of complications during pregnancy [7, 23].

The complications which could be associated with uterine fibroids in pregnancy include degenerative changes which commonly cause abdominal pain, miscarriages, malposition/malpresentation, intrauterine growth restriction, antepartum haemorrhage, preterm labour, obstructed labour, postpartum haemorrhage, and high caesarean section rates [16–19, 24–26].

The occurrence of some of these complications in pregnancy could lead to the abandonment of the usual conservative management of uterine fibroid in pregnancy. The option of myomectomy during pregnancy must be carefully considered. There is much increased uterine vascularization during pregnancy. Therefore, myomectomy may result in excessive blood loss which may lead to inevitable hysterectomy [5, 23] or maternal mortality [16]. In the presence of intractable

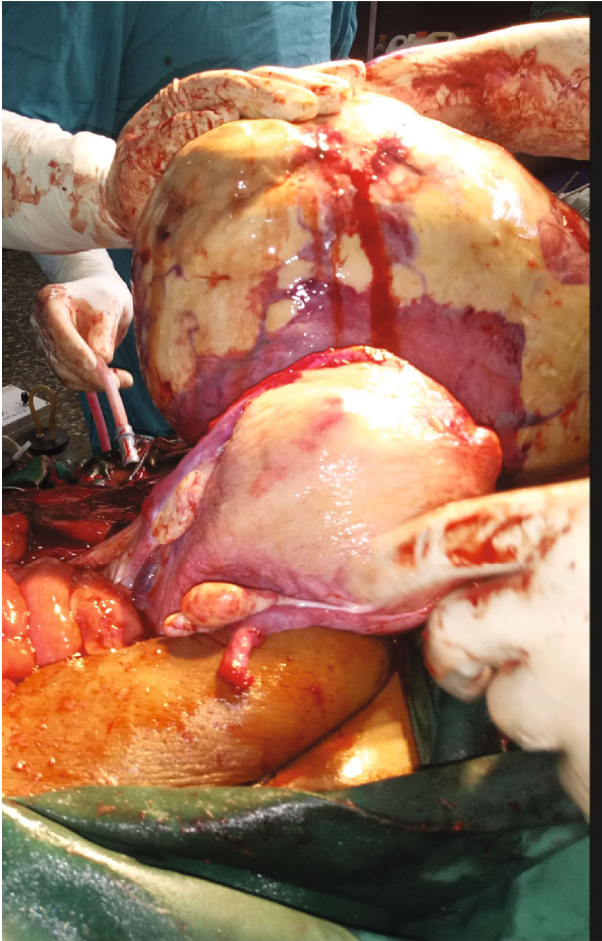


FIGURE 2: Relationship of the fibroid to the uterus.

symptomatology, however, we encourage treatment to be individualized to get optimal results.

Our index patient noticed progressive abdominal swelling over seven years but did not present for treatment in any hospital before she got pregnant. She had responded well to conservative management; thus, antepartum myomectomy was not performed. Despite comprehensive counseling, we had no way of ensuring that the patient would return for myomectomy after the delivery of the baby. Also, the lady was primiparous; thus, she would likely have returned with more complications due to uterine fibroids in subsequent pregnancies. Caesarean myomectomy was further adjudged to be safe in this case because the ultrasound scan showed a single, large, subserous fibroid nodule. Based upon the above considerations, an intracapsular caesarean myomectomy was successfully performed after delivery of the baby. This is the currently recommended technique for caesarean myomectomy [27, 28] which is safe, feasible, and reliable if correctly performed in carefully selected patients [27–29]. Intracapsular myomectomy technique is currently recommended because the fibroid pseudocapsule (which is preserved during the procedure) has been shown to contain many neuropeptides and neurotransmitters. These substances play a positive role in wound healing and improvement in subsequent sexual and reproductive functions [30].

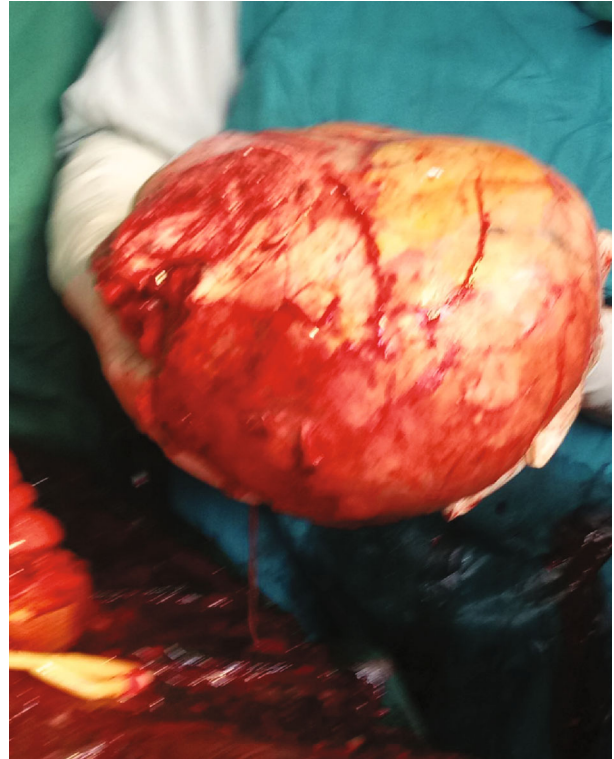

FIGURE 3: Removed fibroid nodule.

Our index patient is nulliparous and thus would benefit from this surgical technique. Thereafter, she had no postoperative complications due to good preoperative preparations, good surgical skills, and good postpartum monitoring which anticipated and prevented complications.

We decided to document our experience in our clinical setting where many patients may present with large and/or symptomatic uterine fibroids in pregnancy. This goes to show that caesarean myomectomy could be performed with good results in carefully selected cases.

#### 4. Conclusion

Uterine fibroids in pregnancy are usually asymptomatic, and thus, the first line of management is conservative. However, in the presence of complications, good selection criteria need to be applied to individualize patient care for optimal results. Caesarean myomectomy can be performed with good results in carefully selected cases, as was obtained in this case report.

#### Data Availability

Availability of data is not required.

#### Conflicts of Interest

The authors declare that there is no conflict of interests regarding the publication of this paper.



## Authors' Contributions

The lead author undertook the major part in writing and researching this report, with the review, editing, and plagiarism verification done by the second author.

## References

- [1] S. G. Vitale, A. Tropea, D. Rossetti, M. Carnelli, and A. Cianci, "Management of uterine leiomyomas in pregnancy: review of literature," *Updates in Surgery*, vol. 65, no. 3, pp. 179–182, 2013.
- [2] R. G. Steward, H. W. DenHartog, and A. R. Katz, "Giant uterine leiomyomata," *Fertility and Sterility*, vol. 95, no. 3, pp. 1121.e15–1121.e17, 2011.
- [3] F. O. Okogbo, O. C. Ezechi, O. M. Loto, and P. M. Ezeob, "Uterine leiomyomata in South-Western Nigeria: a clinical study of presentations and management outcome," *African Health Sciences*, vol. 11, no. 2, pp. 271–278, 2011.
- [4] S. K. Sunkara, M. Khairy, T. El-Toukhy, Y. Khalaf, and A. Coomarasamy, "The effect of intramural fibroids without uterine cavity involvement on the outcome of IVF treatment: a systematic review and meta-analysis," *Human Reproduction*, vol. 25, no. 2, pp. 418–429, 2010.
- [5] D. W. Panchal, H. U. Doshi, P. Singh, and P. Rohit, "Co-existing large fibroid in pregnancy: a case report," *Gujarat Medical Journal*, vol. 67, no. 2, pp. 110–112, 2012.
- [6] G. A. Vilos, C. Allaire, P. Y. Laberge et al., "The management of uterine leiomyomas," *Journal of Obstetrics and Gynaecology Canada*, vol. 37, no. 2, pp. 157–178, 2015.
- [7] M. Deveer, R. Deveer, Y. Engin-Ustun et al., "Comparison of pregnancy outcomes in different localizations of uterine fibroids," *Clinical and Experimental Obstetrics & Gynecology*, vol. 39, pp. 516–518, 2012.
- [8] K. Leach, L. Khatain, and K. Tocce, "First trimester myomectomy as an alternative to termination of pregnancy in a woman with a symptomatic uterine leiomyoma: a case report," *Journal of Medical Case Reports*, vol. 5, no. 1, p. 571, 2011.
- [9] M. E. Aziken, J. A. Osaikhuwuomwan, A. P. Osemwenkha, O. E. Olokor, I. Iribhogbe, and C. U. Uwagboe, "Pregnancies complicated by uterine fibroids: a case series on myomectomy in early pregnancy," *Tropical Journal of Obstetrics and Gynaecology*, vol. 34, no. 2, pp. 160–164, 2017.
- [10] A. Basso, M. R. Catalano, G. Loverro et al., "Uterine fibroid torsion during Pregnancy: A case of Laparotomic myomectomy at 18 Weeks' gestation with systematic review of the Literature," *Case Reports in Obstetrics and Gynecology*, vol. 2017, Article ID 4970802, 11 pages, 2017.
- [11] J. O. Awoleke, "Myomectomy during caesarean birth in Fibroid-Endemic, Low-Resource settings," *Obstetrics and Gynecology International*, vol. 2013, Article ID 520834, 6 pages, 2013.
- [12] D. H. Kwon, J. E. Song, K. R. Yoon, and K. Y. Lee, "The safety of cesarean myomectomy in women with large myomas," *Obstetrics & Gynecology Science*, vol. 57, no. 5, pp. 367–372, 2014.
- [13] S. G. Vitale, F. Padula, and F. A. Gulino, "Management of uterine fibroids in pregnancy: recent trends," *Current Opinion in Obstetrics and Gynecology*, vol. 27, no. 6, pp. 432–437, 2015.
- [14] D. Song, W. Zhang, M. C. Chames, and J. Guo, "Myomectomy during cesarean delivery," *International Journal of Gynecology & Obstetrics*, vol. 121, no. 3, pp. 208–213, 2013.
- [15] A. Tinelli, "Myoma in pregnancy and Cesarean myomectomy: a matter of debate for a long time," *International Journal of Gynecology & Clinical Practices*, vol. 1, no. 1, p. 104, 2014.
- [16] D. S. Abam and T. Kasso, *Uterine fibroids and pregnancy: a review of the challenges*. *Obstetrics*, Hassan Salah Abduljabber, IntechOpen, 2017.
- [17] P. C. Klatsky, N. D. Tran, A. B. Caughey, and V. Y. Fujimoto, "Fibroids and reproductive outcomes: a systematic literature review from conception to delivery," *American Journal of Obstetrics and Gynecology*, vol. 198, no. 4, pp. 357–366, 2008.
- [18] R. Zhao, X. Wang, L. Zou et al., "Adverse obstetric outcomes in pregnant women with uterine fibroids in China: a multicenter survey involving 112,403 deliveries," *PLoS One*, vol. 12, no. 11, article e0187821, 2017.
- [19] G. N. Milazzo, A. Catalano, V. Badia, M. Mallozzi, and D. Caserta, "Myoma and myomectomy: poor evidence concern in pregnancy," *Journal of Obstetrics and Gynaecology Research*, vol. 43, no. 12, pp. 1789–1804, 2017.
- [20] C. Ezeama, J. I. Ikechebelun, N. J. Obiechina, and N. N. Ezeama, "Clinical presentation of uterine fibroids in Nnewi, Nigeria: a 5-year review," *Annals of Medical and Health Sciences Research*, vol. 2, no. 2, pp. 114–118, 2012.
- [21] M. A. Adegbesan-Omilabu, K. S. Okunade, and A. Gbadegesin, "Knowledge of, perception of, and attitude towards uterine Fibroids among women with fibroids in Lagos, Nigeria," *Scientifica*, vol. 2014, Article ID 809536, 5 pages, 2014.
- [22] A. Ciavattini, N. Clemente, G. Deli-Carpini, J. Di Guiseppa, S. R. Giannubilo, and A. L. Tranquilli, "Number and sizes of uterine fibroids and obstetric outcomes," *The Journal of Maternal-Fetal & Neonatal Medicine*, vol. 28, pp. 484–488, 2015.
- [23] H. J. Lee, E. R. Norwitz, and J. Shaw, "Contemporary management of fibroids in pregnancy," *Reviews in Obstetrics and Gynecology*, vol. 3, no. 1, pp. 20–27, 2010.
- [24] B. H. Radhika, K. Nak, S. Shreelatha, and H. Vana, "Case series: pregnancy outcome in patients with uterine fibroids," *Journal of Clinical and Diagnostic Research*, vol. 9, no. 10, pp. 01–04, 2015.
- [25] I. Sarwar, S. Habib, A. Bibi, N. Malik, and Z. Parveen, "Clinical audit of foetomaternal outcome in pregnancies with fibroid uterus," *Journal of Ayub Medical College Abbottabad*, vol. 24, no. 1, pp. 79–82, 2012.
- [26] O. F. Morgan, R. D. Pina, G. E. Elorriaga, B. J. Baez, C. E. Quevedo, and G. F. J. Peraza, "Uterine leiomyomas during pregnancy and its impact on obstetric outcome," *Ginecologia y Obstetricia de Mexico*, vol. 79, no. 8, pp. 467–473, 2011.
- [27] A. Tinelli, A. Malvasi, O. A. Mynbaev et al., "The surgical outcome of Intracapsular cesarean myomectomy. A match control study," *The Journal of Maternal-Fetal Medicine*, vol. 27, no. 1, pp. 66–71, 2014.
- [28] R. Sparić, S. Kadija, A. Stefanović et al., "Cesarean myomectomy in modern obstetrics: more light and fewer shadows," *The Journal of Obstetrics and Gynaecology Research*, vol. 43, no. 5, pp. 798–804, 2017.
- [29] A. R. Chauhan, "Cesarean myomectomy: necessity or opportunity?," *The Journal of Obstetrics and Gynecology of India*, vol. 68, no. 6, pp. 432–436, 2018.
- [30] A. Tinelli, O. A. Mynbaev, R. Sparić et al., "Angiogenesis and vascularization of uterine leiomyoma: clinical value of pseudocapsule containing peptides and neurotransmitters," *Current Protein & Peptide Science*, vol. 18, no. 2, pp. 129–139, 2017.