

## Case Report

# Metastatic Recurrence of Typical Pulmonary Carcinoid Accompanied by Carcinoid Syndrome, Successfully Treated with Octreotide LAR

Asako Yanagisawa,<sup>1</sup> Satoshi Hirano,<sup>2</sup> Shinichiro Shimizu,<sup>3</sup> Takuma Hiroishi,<sup>1</sup> Kohei Shikano,<sup>1</sup> Noriko Hayama,<sup>1</sup> Tetsuo Fujita,<sup>1</sup> Hiroyuki Amano,<sup>1</sup> Makoto Nakamura,<sup>1</sup> Sukeyuki Nakamura,<sup>1</sup> and Hiroshi Tabeta<sup>1</sup>

<sup>1</sup>Department of Respiratory Medicine, Funabashi Municipal Medical Center, Chiba, Japan

<sup>2</sup>Department of Medical Oncology, Funabashi Municipal Medical Center, Chiba, Japan

<sup>3</sup>Department of Pathology, Funabashi Municipal Medical Center, Chiba, Japan

Correspondence should be addressed to Satoshi Hirano; [shirano@mmc.funabashi.chiba.jp](mailto:shirano@mmc.funabashi.chiba.jp)

Received 9 September 2017; Accepted 23 November 2017; Published 28 December 2017

Academic Editor: Jeanine M. Buchanich

Copyright © 2017 Asako Yanagisawa et al. This is an open access article distributed under the Creative Commons Attribution License, which permits unrestricted use, distribution, and reproduction in any medium, provided the original work is properly cited.

We present a case of metastatic recurrence of carcinoid tumor accompanied by carcinoid syndrome in a 68-year-old Japanese man, 12 years after resection of typical pulmonary carcinoid. Histopathologic examination from percutaneous liver biopsy revealed metastatic typical carcinoid. Clinical symptoms gradually improved after administration of octreotide LAR. Two years after starting treatment, the disease remains well controlled. This case report illustrates the possibility of antiproliferative effects of octreotide LAR on typical pulmonary carcinoid.

## 1. Introduction

Typical pulmonary carcinoid is known as a low-grade subtype of lung neuroendocrine tumor (NET) and is characterized by an indolent nature. Recurrence of typical pulmonary carcinoid after complete resection is very rare (3–5%) [1]. The frequency of carcinoid syndrome among lung NETs is also very low [2]. Somatostatin analogues such as octreotide have been reported to improve the symptoms of carcinoid syndrome [3]. Furthermore, octreotide long-acting repeatable (LAR) has shown antitumor activity against midgut NETs [4].

## 2. Case

A 68-year-old Japanese man was referred to our hospital because of multiple hyperechoic lesions in the liver without any symptoms. The patient was a former smoker with a 45-pack-year history. Twelve years prior to this presentation, he

had undergone thoracoscopic left upper lobectomy for typical pulmonary carcinoid (pT1N0M0, stage I). Histopathologic examination of the surgical specimen revealed finely granular nuclear chromatin, eosinophilic cytoplasm, and rosette formation (Figure 1(a)). The immunohistology was positive for synaptophysin, chromogranin A, and CD56 (Figure 1(b)). The presence of 1 mitosis per 2 mm<sup>2</sup> and absence of necrosis were consistent with typical carcinoid. The hilar and mediastinal lymph nodes were negative for any tumor, and the surgical margins as well were free of any tumor.

The patient had a history of atrial fibrillation. Physical examination revealed no abnormalities. Computed tomography (CT) with intravenous contrast of the abdomen revealed multiple low-density areas. Percutaneous liver biopsy of one of the lesions demonstrated well-differentiated tumor with positive expressions of chromogranin A, synaptophysin, and CD56 (Figure 2). The presence of 1 mitosis per 2 mm<sup>2</sup> and no necrosis were also demonstrated, which

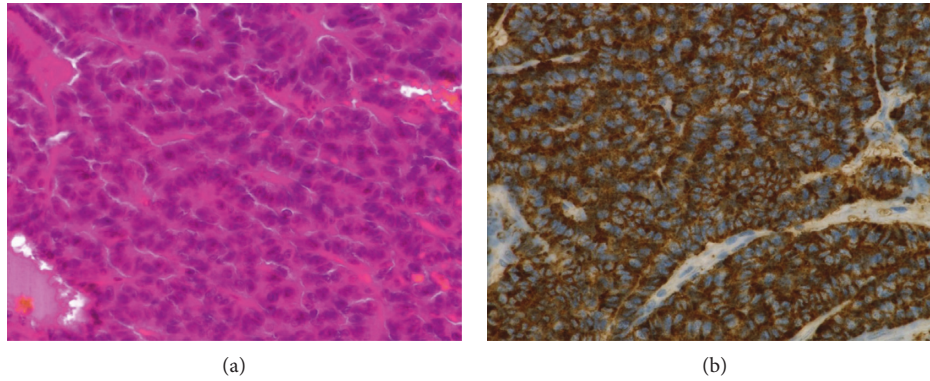


FIGURE 1: Histologic examination of surgically resected pulmonary carcinoid tumor shows finely granular nuclear chromatin, eosinophilic cytoplasm, and rosette formation (a) and positive expression of chromogranin A (b).

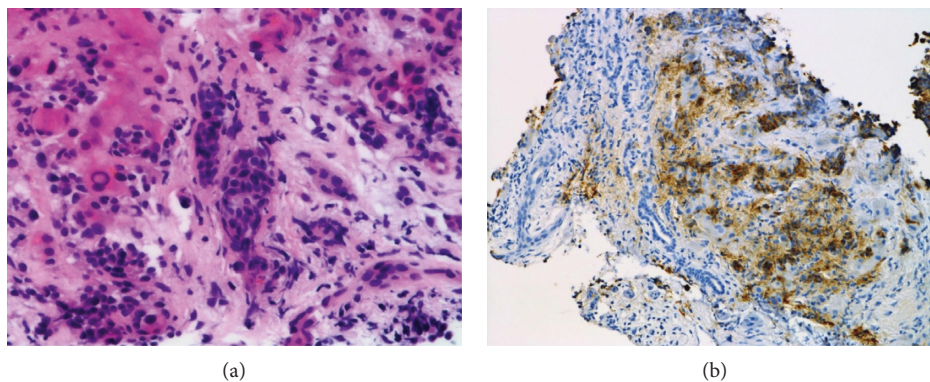


FIGURE 2: Histologic examination of a liver biopsy specimen shows a well-differentiated tumor (a) with positive expression of chromogranin A (b).

was compatible for metastatic typical carcinoid. During 6 months of close observation, the patient developed chronic diarrhea resulting in 12 kg of weight loss. His general condition worsened, and he was hospitalized.

Physical examination showed hepatomegaly and wheezing. Levels of neuron-specific enolase and  $\alpha$ -fetoprotein were both elevated, at 24.7 ng/ml (normal range (NR) < 16.3 ng/ml) and 56 ng/ml (NR < 10 ng/ml), respectively. Blood 5-hydroxyindole acetate (5-HIAA), urine 5-HIAA, and serotonin degradation metabolite levels were elevated at 1121 ng/ml (NR 57–230 ng/ml), 472 ng/ml (NR 1.8–6.1 ng/ml), and 86.9 mg/13 h (NR 1–6 mg/24 h), respectively, confirming the diagnosis of carcinoid syndrome. Chest CT showed no abnormalities. Abdominal contrast-enhanced CT revealed multiple tumors in the liver and spleen, as well as hepatomegaly (Figure 3). Magnetic resonance imaging (MRI) of the brain revealed an enhanced nodular lesion in the right occipital lobe, compatible with a brain metastasis.

Considering that immunostaining for somatostatin receptor 2 antibody was scored as 3 (circumferential membranous reactivity in >50% of tumor cells), subcutaneous octreotide therapy was started at a dose of 100  $\mu$ g/day (Figure 4). Blood serotonin, blood 5-HIAA, and neuron-specific enolase levels decreased markedly and diarrhea gradually improved. Following 20 mg of LAR octreotide via intramuscular injections every 4 weeks, the dose was

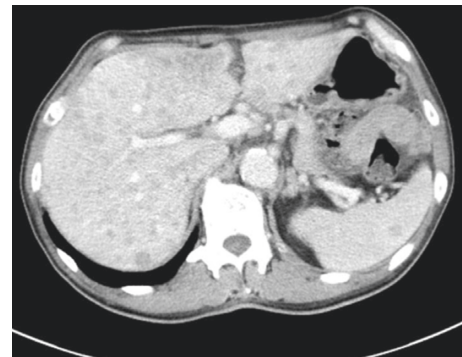


FIGURE 3: Abdominal contrast-enhanced CT shows multiple low-density areas, hepatomegaly, and metastasis to the spleen.

increased to 30 mg every 4 weeks because of persistent diarrhea. Two years after starting octreotide therapy, the disease is well controlled with almost no symptoms, except for transient ischemic attack.

### 3. Discussion

Pulmonary carcinoid tumor is a rare NET that accounts for less than 2% of all lung tumors. Good prognosis can be expected following complete surgical resection of

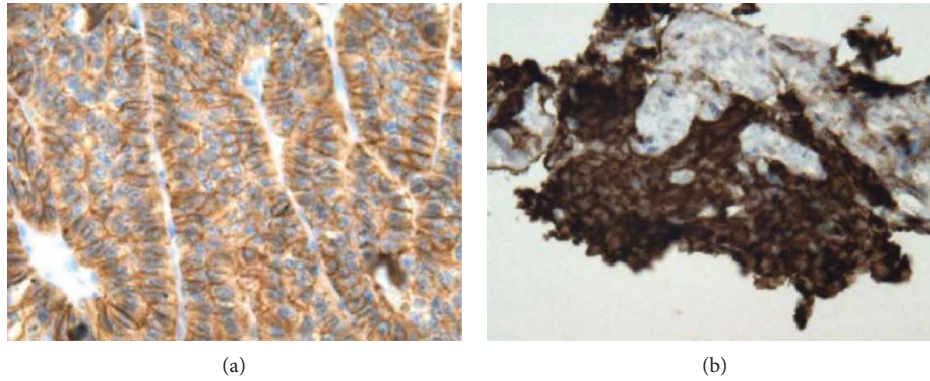


FIGURE 4: Immunohistochemical analysis demonstrates immunoreactivity for somatostatin receptor 2 antibody immunostaining in most tumor cells in the lung (a) and liver (b).

pulmonary carcinoid tumor. The recurrence rate for typical carcinoid is lower (3.6%) than that of atypical carcinoid (33.3%) [5]. Histological subtype, staging, and nodal status are reported to be significant predictors of disease-free survival [6]. In contrast, Maurizi showed that only histological subtype (and not nodal status) can influence disease-free survival, with a statistically significant advantage for typical carcinoid [7]. The distinction between typical and atypical carcinoid is thus very important in the determination of prognosis. The WHO 2015 classification for lung NETs states that the defining features of atypical carcinoid are the presence of 2–10 mitoses per  $2\text{ mm}^2$  and/or the presence of necrosis [8]. As for atypical carcinoid, Arrigoni et al. [9] first described the histological criteria for atypical bronchopulmonary carcinoid tumors in 1972, namely, increased mitotic activity with 5–10 mitoses per  $2\text{ mm}^2$  (10 high-power field (HPF)), nuclear pleomorphism, and irregularity with hyperchromatism and prominent nucleoli, areas of increased cellularity with disorganization, and necrosis. Travis et al. reported increased mitotic activity as the only independent predictor of prognosis in the criteria described by Arrigoni [10]. He proposed that either a mitotic count  $\geq 2$  and  $<10$  per  $2\text{ mm}^2$  (10 HPF) in viable tumor or the presence of necrosis should be the histologic criterion for atypical carcinoid, because atypical carcinoid would be underestimated if the mitotic range is set between 5 and 10 mitoses (10 high-powered fields), and the presence of necrosis is indicative of poor prognosis.

Only a small number of patients with typical carcinoid experience recurrences, with a median time to recurrence of 4 years (range, 0.8–12 years), longer than that for atypical carcinoid [11]. As a result, few case reports have addressed the late recurrence of typical carcinoid tumors. Our case was valuable in that liver metastases occurred more than 10 years after complete resection of the primary tumor.

The primary lesion was diagnosed as typical carcinoid. However, part of the primary lesion showed conspicuous nucleoli and high cellularity, consistent with atypical carcinoid according to the former criteria [9]. These features may indicate the potential for recurrence or metastasis of typical carcinoid. Arrigoni et al. reported that 70% of 23 carcinoids with such histologic features exhibited metastasis,

as compared to 5.6% of histologically typical carcinoid [9]. Atypical features including high cellularity and prominent nucleoli could be assumed to be related to metastasis to the liver, and the low mitotic count was associated with late recurrence in our case.

Whether liver metastases originated from the lung in our case represents an important issue, because there is a possibility of the presence of another primary site. When liver metastases are demonstrated, CT of the chest and abdomen, abdominal ultrasonography, upper gastrointestinal endoscopy, and colonoscopy are performed to exclude primary tumors other than those of the lung, but no other gastroenteropancreatic neuroendocrine tumors were found in our case. Brain metastasis without pulmonary lesions is not common for primary sites other than the lung.

Patients with carcinoid syndrome display a shorter overall survival (median, 5 years) than patients without carcinoid syndrome (5.6 years) [2]. Patients with NETs and carcinoid syndrome show marked impairments in multiple areas. Carcinoid syndrome also affects patients' quality of life. Although the frequency of carcinoid syndrome in lung NETs is very low, our patient was diagnosed with typical pulmonary carcinoid and carcinoid syndrome.

Somatostatin receptor scintigraphy (SRS) is useful for the diagnosis of neuroendocrine tumors [12]. Accumulations on SRS reflect the degree of tumor differentiation, and SRS shows high sensitivity for the detection of low-grade neuroendocrine tumors. SRS is a helpful option for detecting metastatic lesions that are hard to find by other imaging modalities and for predicting the outcomes of octreotide treatment [13]. Although we did not perform SRS, strongly positive results for somatostatin receptor 2 were seen on immunohistochemical staining [14]. Octreotide suppresses the production of physiologically active substances through binding to somatostatin receptors on tumor cells [15]. Octreotide can be expected to have somatostatin receptor-mediated and antiangiogenic antiproliferative effects [16].

The LAR formulation of octreotide inhibits tumor growth in patients with metastatic midgut neuroendocrine tumors [4]. Octreotide treatment resulted in control of carcinoid syndrome and tumor reduction or complete regression in 43% of patients with liver metastases of

pulmonary atypical carcinoid [17]. An antiproliferative effect of octreotide on pulmonary carcinoid tumor can be expected. However, few case reports have addressed the antiproliferative effects of octreotide LAR on typical pulmonary carcinoid. An antiproliferative effect of another long-acting somatostatin analogue lanreotide was demonstrated in a study of more than 200 patients with somatostatin receptor-positive enteropancreatic neuroendocrine tumors with Ki-67 values of less than 10% [18]. Although the patients in this study were thought to have more indolent tumors, the estimated rates of progression-free survival were 65.1% in the lanreotide group and 33.0% in the placebo group. In our case, carcinoid syndrome was well controlled after administration of octreotide LAR, which also resulted in a long period of disease stabilization. Considering the median PFS of 11.3 months in the placebo plus octreotide LAR group in the RADIANT-2 trial [3], our case may indicate that treatment with octreotide LAR is associated with longer tumor stabilization in typical carcinoid, which has the lower mitotic rate.

In summary, this case report illustrates the possibility of antiproliferative effects of octreotide LAR on typical pulmonary carcinoid.

## Ethical Approval

The study design was exempt from ethics review board approval.

## Consent

The patient provided informed consent.

## Conflicts of Interest

The authors declare no conflicts of interest and no financial arrangements with any companies.

## Acknowledgments

The authors thank Dr. Robert Yoshiyuki Osamura from Diagnostic Pathology Center at International University of Health and Welfare (IUHW) Mita Hospital in Tokyo for somatostatin receptor 2 immunohistochemical staining.

## References

- [1] E. M. Wolin, "Challenges in the diagnosis and management of well-differentiated neuroendocrine tumors of the lung (typical and atypical carcinoid): current status and future considerations," *Oncologist*, vol. 20, no. 10, pp. 1123–1131, 2015.
- [2] D. M. Halperin, C. Shen, A. Dasari et al., "Frequency of carcinoid syndrome at neuroendocrine tumour diagnosis: a population-based study," *Lancet Oncology*, vol. 18, no. 4, pp. 525–534, 2017.
- [3] M. E. Pavel, J. D. Hainsworth, E. Baudin et al., "Everolimus plus octreotide long-acting repeatable for the treatment of advanced neuroendocrine tumours associated with carcinoid syndrome (RADIANT-2): a randomised, placebo-controlled, phase 3 study," *The Lancet*, vol. 378, no. 9808, pp. 2005–2012, 2011.
- [4] A. Rinke, H. H. Müller, C. Schade-Brittinger et al., "Placebo-controlled, double-blind, prospective, randomized study on the effect of octreotide LAR in the control of tumor growth in patients with metastatic neuroendocrine midgut tumors: a report from the PROMID Study Group," *Journal of Clinical Oncology*, vol. 27, no. 28, pp. 4656–4663, 2009.
- [5] H. Asamura, T. Kameya, Y. Matsuno et al., "Neuroendocrine neoplasms of the lung: a prognostic spectrum," *Journal of Clinical Oncology*, vol. 24, no. 1, pp. 70–76, 2006.
- [6] P. C. Lee, N. C. Osakwe, N. Narula et al., "Predictors of disease-free survival and recurrence in patients with resected bronchial carcinoid tumors," *Thoracic and Cardiovascular Surgeon*, vol. 64, no. 2, pp. 159–165, 2016.
- [7] G. Maurizi, M. Ibrahim, C. Andreotti et al., "Long-term results after resection of bronchial carcinoid tumour: evaluation of survival and prognostic factors," *Interactive Cardio Vascular and Thoracic Surgery*, vol. 19, no. 2, pp. 239–244, 2014.
- [8] W. D. Travis, E. Brambilla, A. P. Burke et al., *WHO Classification of Tumours of the Lung, Pleura, Thymus and Heart*, International Agency for Research on Cancer, Lyon, France, 2015.
- [9] M. G. Arrigoni, L. B. Woolner, and P. E. Bernatz, "A typical carcinoid tumors of the lung," *Journal of Thoracic and Cardiovascular Surgery*, vol. 64, no. 3, pp. 413–421, 1972.
- [10] W. D. Travis, W. Rush, D. B. Flieder et al., "Survival analysis of 200 pulmonary neuroendocrine tumors with clarification of criteria for atypical carcinoid and its separation from typical carcinoid," *American Journal of Surgical Pathology*, vol. 22, no. 8, pp. 934–944, 1998.
- [11] F. Lou, I. Sarkaria, C. Pietanza et al., "Recurrence of pulmonary carcinoid tumors after resection: implications for postoperative surveillance," *Annals of Thoracic Surgery*, vol. 96, no. 4, pp. 1156–1162, 2013.
- [12] F. Gibril, J. C. Reynolds, J. L. Doppman et al., "Somatostatin receptor scintigraphy: its sensitivity compared with that of other imaging methods in detecting primary and metastatic gastrinomas. A prospective study," *Annals of Internal Medicine*, vol. 125, no. 1, pp. 26–34, 1996.
- [13] G. D. Slooter, A. Mearadji, W. A. Breeman et al., "Somatostatin receptor imaging, therapy and new strategies in patients with neuroendocrine tumours," *British Journal of Surgery*, vol. 88, no. 1, pp. 31–40, 2001.
- [14] G. D. Slooter, A. Mearadji, W. A. Breeman et al., "Somatostatin receptor type 2A immunohistochemistry in neuroendocrine tumors: a proposal of scoring system correlated with somatostatin receptor scintigraphy," *Modern Pathology*, vol. 20, no. 11, pp. 1172–1182, 2007.
- [15] M. E. Caplin, E. Baudin, P. Ferolla et al., "Pulmonary neuroendocrine (carcinoid) tumors: European Neuroendocrine Tumor Society expert consensus and recommendations for best practice for typical and atypical pulmonary carcinoids," *Annals of Oncology*, vol. 26, no. 8, pp. 1604–1620, 2015.
- [16] K. Oberg, "Cancer: antitumor effects of octreotide LAR, a somatostatin analog," *Nature Reviews Endocrinology*, vol. 6, no. 4, pp. 188–189, 2010.
- [17] P. L. Filosso, E. Ruffini, A. Oliaro et al., "Long-term survival of atypical bronchial carcinoids with liver metastases, treated with octreotide," *European Journal of Cardio-Thoracic Surgery*, vol. 21, no. 5, pp. 913–917, 2002.
- [18] M. E. Caplin, M. Pavel, J. B. Cwikla et al., "Lanreotide in metastatic enteropancreatic neuroendocrine tumors," *New England Journal of Medicine*, vol. 371, no. 3, pp. 224–233, 2014.



**Hindawi**  
Submit your manuscripts at  
<https://www.hindawi.com>

