

Case Report

Schwannoma of the Base of the Tongue: A Case Report of a Rare Disease and Review of Literatures

Mohd. Yusuf Haider ¹, **Manjur Rahim**,¹ **N. M. K. Bashar**,² **Md. Zakir Hossain**,³
and **Sk Md Jaynul Islam**⁴

¹Department of ENT, Colonel Malek Medical College, Manikganj, Bangladesh

²Department of ENT, 250 Bed District Hospital, Manikganj, Bangladesh

³Department of Anesthesiology, Colonel Malek Medical College, Manikganj, Bangladesh

⁴Armed Forces Institute of Pathology, Dhaka, Bangladesh

Correspondence should be addressed to Mohd. Yusuf Haider; myhaider05@gmail.com

Received 2 January 2020; Accepted 30 November 2020; Published 31 December 2020

Academic Editor: Christophoros Foroulis

Copyright © 2020 Mohd. Yusuf Haider et al. This is an open access article distributed under the Creative Commons Attribution License, which permits unrestricted use, distribution, and reproduction in any medium, provided the original work is properly cited.

Background. Schwannoma is a benign nerve sheath tumor. It was first identified by Virchow in 1908. These tumors can emerge from any nerve covered with a Schwann cell sheath, including the cranial nerves (with the exception of the optic and olfactory nerves), the spinal nerves, and the autonomous nervous system (Harada H, Omura K and Maeda A, 2001). **Case Presentation.** A 28-year-old male farmer presented with a swelling at the right side of the base of tongue extending into the oral tongue. It was identified incidentally by his newly married wife while he was yawning. It was asymptomatic. The patient had no difficulty in chewing, swallowing, or phonation and also no sensory or taste abnormalities. The tongue movements were normal. **Conclusions.** Diagnosis of schwannoma should be considered for a smooth, painless, firm swelling in the tongue. A schwannoma of the tongue may grow large enough before producing any symptom. Around 25–40% of schwannoma happen within the head and neck region, and among these, 1–12% occurs in the oral cavity, most regularly the tongue or mouth floor. Schwannoma of the tongue does not show any age or sex predisposition. It usually presents as a painless lump in the tongue, but when it grows larger than 3.0 cm, it may produce dysphagia, pain, or discomfort and change in the quality of voice. Here, we report a case of large (4 cm × 3 cm) asymptomatic schwannoma of the tongue in a 28-year-old male patient and review the literature available during the last 61 years.

1. Introduction

Schwannoma is a benign nerve sheath tumor. It was first identified by Virchow in 1908. These tumors can emerge from any nerve covered with a Schwann cell sheath, including the cranial nerves (with the exception of the optic and olfactory nerves), the spinal nerves, and the autonomous nervous system [1]. When the nerve of origin is small, it can be difficult to demonstrate its connection with a given tumor. On the other hand, if the site of origin is a larger

nerve, it is observed that the nerve fibers are splayed over the outer side of the capsule instead of being absorbed into the tumor mass [2]. About 25–45% of all schwannomas occur in the head and neck [3]. Around 1–12% of these occur intraorally [4, 5] with the tongue being the most common site [5, 6]. Although there are many case reports of tongue schwannomas in the literature, after Hatziotis et al. [6], there has been no comprehensive review of the literature. We present a case of tongue schwannoma and study the literature available from the last 61 years (1959–2019).

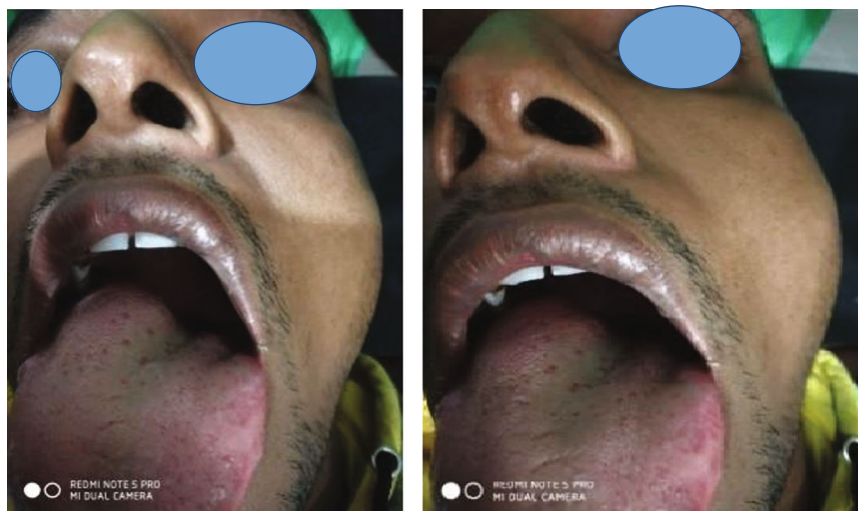


FIGURE 1: Large asymptomatic swelling at posterolateral aspect of right side of tongue.

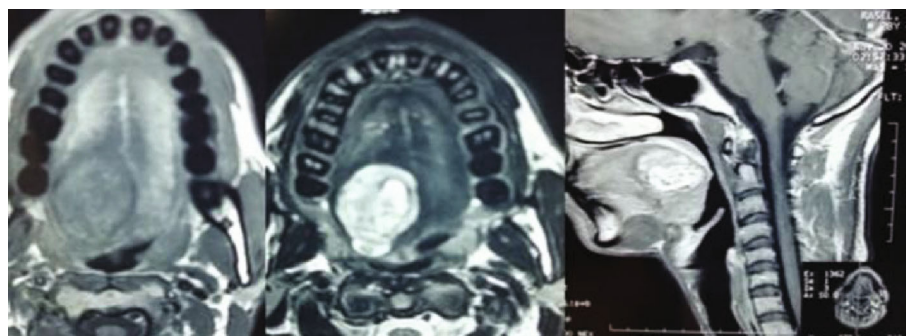


FIGURE 2: Axial T1 and T2 and sagittal T1-weighted magnetic resonance image showing a well-defined mass centered right to the midline in the base of the tongue. The tumor has a smooth well-defined border, with no invasion.

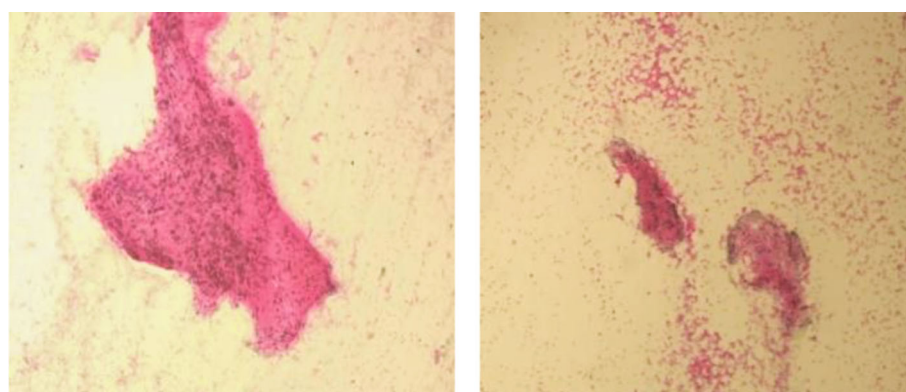


FIGURE 3: FNAC: fragment-of-spindle-cells.

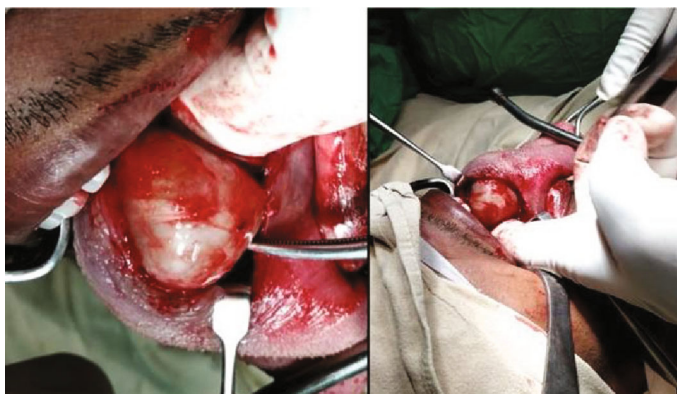


FIGURE 4: Tumor is being removed from the base of the tongue.

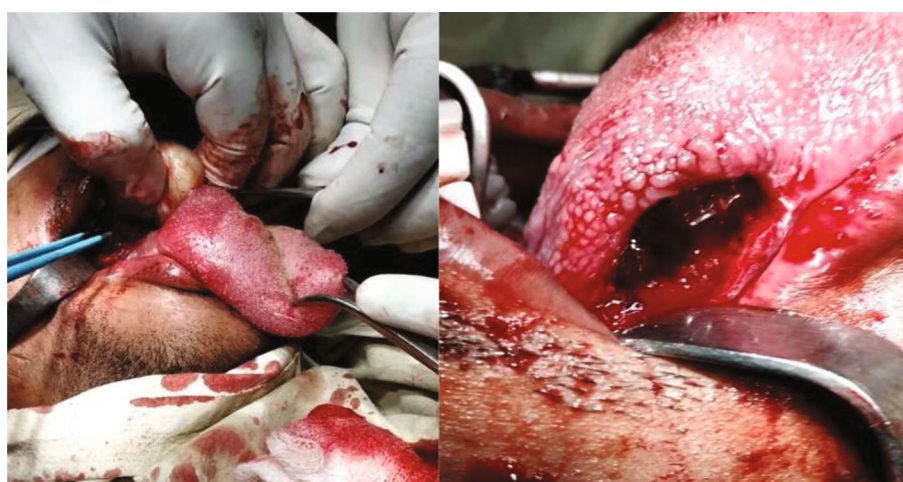

FIGURE 5: Surgical field after removal of the tumour.

2. Materials and Methods

A PubMed search for the terms “tongue schwannoma,” “lingual schwannoma,” “tongue neurilemmoma,” and “lingual neurilemmoma” was conducted with the 1959–2019 date range. The search was restricted to English case reports. Unless the ventral tongue was also involved, mouth floor schwannomas were not included. All the case reports had confirmed the masses’ identity as schwannomas histologically. From the case reports for data analysis, the following elements were extracted: age, gender, location of schwannoma (anterior one-third vs. posterior two-thirds of tongue), symptoms, tumor size, and treatment modality.

3. Case Report

A 28-year-old male farmer presented with a swelling at the right side of the base of tongue extending into the oral tongue. It was identified incidentally by his newly married wife while he was yawning. It was asymptomatic. The patient had no difficulty in chewing, swallowing, or phonation and also no sensory or taste abnormalities. The tongue movements were normal.

On examination, there was an oval swelling at the right side of base of the tongue measuring about 4 cm × 3 cm (Figure 1). The surface was smooth, margin regular, and no discoloration or distortion of tongue epithelium. It was nontender, firm in consistency, and was not fixed with underlying or overlying structures. The remaining oral cavity examination was normal; nasopharyngolaryngoscopy revealed no abnormality in the adjacent areas. There was no cervical lymph node enlargement. Clinically, it appeared like a dermoid cyst or lipoma. MRI of the tongue manifested hyperintense well-circumscribed soft tissue mass in the right half of the base of the tongue on T1/T2-weighted image (Figure 2). It was evaluated with FNAC which revealed benign mesenchymal spindle cell neoplasm, suggestive of nerve sheath tumor with possibility of schwannoma (Figure 3). The patient underwent transoral total excision of the mass under general anesthesia with nasotracheal intubation. For the proper visualization of the base of tongue, frenulum of tongue was incised; tongue was released from floor of mouth and pulled out. An incision was given in right lateral margin over the swelling. After splitting the mucosa, mass is exposed, mobilized by blunt dissection, and excised totally (Figures 4–6). Haemostasis was ensured, and wound closed in layers. Histopathological report

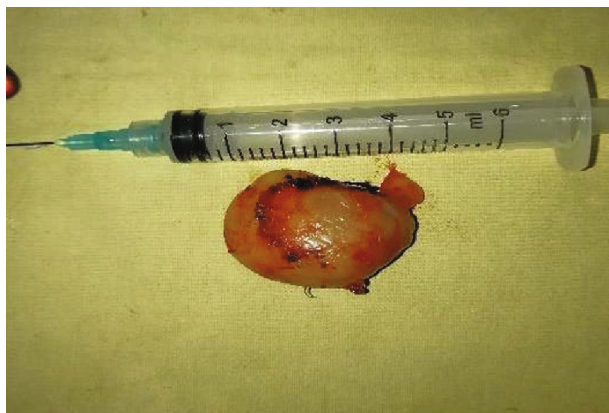

FIGURE 6: Excised tumour from the base of the tongue.

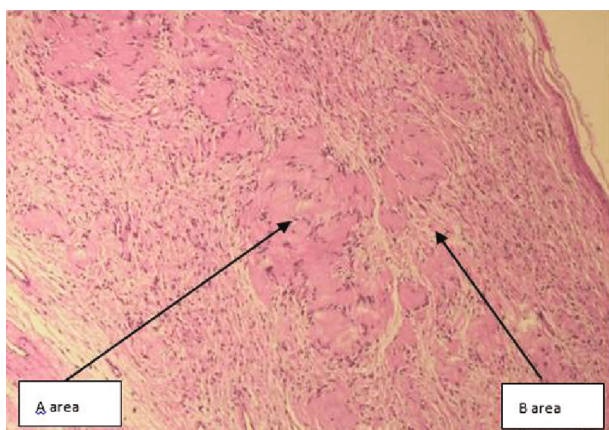


FIGURE 7: Histopathological examination. The lesion is composed of spindle cells with hypercellular Antoni A areas and hypocellular Antoni B areas.

revealed features of schwannoma (Figure 7). For confirmation of the tissue of origin, immunocytochemistry was done and found strongly positive for S100 protein. There was no symptom or sign of recurrence in 12 months post-operative follow-up (Figure 8).

4. Discussion

Though this is not clear of the etiology of the schwannoma, it is known to be derived from nerve sheath Schwann cells, which surround cranial, peripheral, and autonomic nerves [6, 7]. The head and neck are rather common location of this neoplasm. Intraoral schwannoma mainly arise from the tongue, followed by the palate, mouth floor, buccal mucosa, gingiva, lip, and vestibule [8, 9], though the tongue is most commonly involved [10]. The lesion is slow growing, and thus, its onset is usually long before presentation. Lingual schwannoma shows no age or gender predisposition [11]. Usually, it presents as a painless lump in any part of the tongue. The average size at presentation was 2.4 cm. However, when the mass

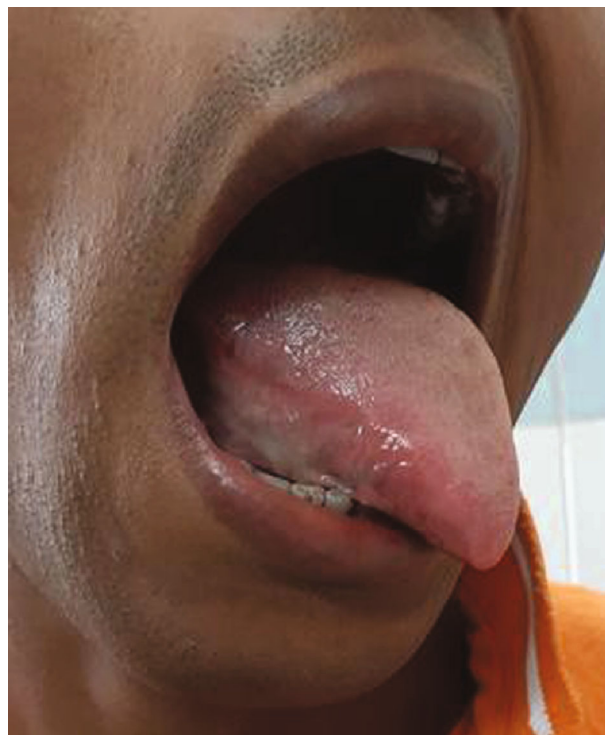

FIGURE 8: The patient followed up after 1 (one) year, and there was no recurrence of the disease.

exceeds 3.0 cm, dysphagia, pain (or discomfort), dysphonia, and voice changes are usually present (Table 1).

In the literature review of 61-year period (from 1959 to 2019), 68 cases schwannoma of the tongue were found, and 54% of them are male, and the rest of them are female. More than half of the cases were posterior tongue schwannomas (56%). According to this review, the patients had feeling of lump cases, respectively.

The mean age at diagnosis was nearly 25 years. Transoral excision was performed in 96% cases. However, for two cases, carbon dioxide laser was used for the tongue-base schwannoma, and in three cases, submandibular approach was used. There was no report of recurrence.

Clinically, the schwannomas may be indistinguishable from other encapsulated benign tumors, because biopsy and histological examination are essential to formulate a correct diagnosis. An excisional biopsy was performed to formulate a correct diagnosis and finally find out that the case was uncomplicated. Imaging has become an integral part of evaluation for tongue base lesions, and thus, a systematic imaging approach should be considered. As demonstrated in Fig. 9, lesions of the tongue can be divided into infectious, neoplastic, and congenital categories. An infectious process, such as an abscess, appears hyperintense on T2WI with a thick rim-enhancing margin [12]. The present case was totally asymptomatic before surgery, and there was no major complication of surgery. The option of complete resection was chosen on the basis of the size of the lesion and the age of the patient.

TABLE 1: Patients and tumor characteristics of tongue schwannomas.

Author	Year	Gender	Age	Size (cm)	Site	Presentation	Surgical approach
Mercantini and Mopper [13]	1959	M	22	1	Anterior	Intermittent pain	Transoral
Cameron [14]	1959	M	25	1.5	Anterior	Lump	Transoral
Chadwick [15]	1964	F	20	2.2	Posterior	Lump	Transoral
Craig [16]	1964	F	8	3	Posterior	Lump	Transoral
Pantazopoulos [17]	1965	F	45	4.5	Posterior	Dysphasia/change in voice	Transoral
Chamber [18]	1965	M	29	5	Posterior	Throat discomfort	Transoral
Fifer et al. [19]	1966	F	28	3	Anterior	Lump	Transoral
Hatziotis and Aspride [20]	1967	M	25	Hazelnut	Posterior	Lump	Transoral
Oles and Werthemier [21]	1967	M	52	1	Anterior	Lump	Transoral
Paliwal et al. [22]	1967	M	32	2.5	Anterior	Lump	Transoral
Crawford et al. [23]	1968	M	23	0.5	Anterior	Lump	Transoral
	1968	M	24	1	Anterior	Lump	Transoral
Das Gupta et al. [24]	1969	F	21	5	Posterior	Pain	Transoral
Bitici [25]	1969	M	40	2.5	Anterior	Slight discomfort	Transoral
Sinha and Samuel [26]	1971	M	23	1.5	Posterior	Dysphagia	Transoral
Mosadomi [27]	1975	M	19	3	Anterior	Painful mass	Transoral
Swangsilpa et al. [28]	1976	M	26	3	Anterior	Lump	Transoral
Sharan and Akhtar [29]	1978	F	30	1.5	Anterior	Change in voice	Transoral
Akimoto et al. [30]	1987	M	15	1	Anterior	Lump	Transoral
Sira et al. [31]	1988	F	18	3	Posterior	Lump	Transoral
Flickinger et al. [32]	1989	F	28	3	Anterior	Lump	Transoral
Talmi et al. [33]	1991	F	75	1	Posterior	Lump	Transoral
Gallesio and Berrone [34]	1992	F	21	1.9	Anterior/base	Dysphonia/paresthesia/chewing difficulty	Transoral
Lopez and Ballistin [10]	1993	M	24	0.6	Anterior	Lump	Transoral
Haring [35]	1994	F	49	2	Anterior	Lump	Transoral
Nakayama et al. [36]	1996	F	40	5.5	Anterior	Lump	Transoral
Dreher et al. [37]	1997	F	31	3	Base	Dysphagia	Transoral
Spandow et al. [38]	1999	M	37	7.9	Posterior	Throat discomfort	Transoral
de Bree et al. [2]	2000	F	24	5	Posterolateral/base	Lump	Submandibular
Pfeifle et al. [39]	2001	F	30	0.3	Anterior	Lump	Transoral
Cinar et al. [40]	2004	M	7	1	Anterior	Lump	Transoral
Bassichis and McMay [41]	2004	M	9	2.3	Posterior/base	Snoring	Transoral
Nakasato et al. [42]	2005	F	9	2	Posterolateral/base	Bleeding/ulceration	Transoral
Hwang et al. [43]	2005	M	23	2.8	Anterior	Lump	Transoral
Lopez-Jornet and Bermejo-Fenoll [44]	2005	M	39	0.8	Posterolateral/base	Lump	Transoral

TABLE 1: Continued.

Author	Year	Gender	Age	Size (cm)	Site	Presentation	Surgical approach
Vafiadis et al. [45]	2005	M	18	3.1	Anterior	Lump	Transoral
Bansal et al. [46]	2005	M	26	4	Posterolateral/ventral	Paresthesia/dysphonia	Transoral
Hsu et al. [7]	2006	M	20	5	Posterior/base	Bleeding	Transoral
Ying et al. [47]	2006	F	26	4	Posterior/base	Dysphagia/otalgia	Transoral
Enoz et al. [48]	2006	M	7	2.5	Anterior/base	Dysphagia/pain	Transoral
Mehrзад et al. [49]	2006	M	49	2.2	Posterior/ventral	Pain	CO ₂ -transoral
Batra et al. [50]	2007	M	30	3	Posterolateral/base	Dysphagia, dyspnea, abscess	Transoral
Ballesteros et al. [51]	2007	F	31	2	Base	Pain	CO ₂ -transoral
Sawhney et al. [52]	2008	F	37	4.6	Posterolateral/base	Dysphagia/snoring	Submandibular
Sethi et al. [53]	2008	F	28	1	Anterolateral/ventral	Lump	Transoral
Pereira et al. [54]	2008	M	12	1.5	Posterolateral/ventral	Lump	Transoral
Cohen and Wang [55]	2009	M	77	0.7	Posterolateral/ventral	Lump	Transoral
Gupta et al. [56]	2009	F	18	1	Anterior/ventral	Lump	Transoral
Mardianpour and Rahbar [57]	2009	M	18	2	Posterior	Dysphagia/change of voice	Transoral
Karaca et al. [58]	2010	F	13	2	Posterolateral/ventral	Dysphagia	Transoral
Cigdem et al. [59]	2010	M	13	2	Anterior/ventral	Lump	Transoral
Jeffcoat et al. [60]	2010	M	68	1.5	Lateral	Lump	Transoral
Naidu and Sinha [61]	2010	M	12	2	Anterolateral/base	Paresthesia/bleeding/ulceration	Transoral
Lukšić et al. [62]	2011	M	10	1.5	Posterolateral/ventral	Lump	Transoral
Batra et al. [63]	2011	F	38	4.2	Posterior/ventral	Dysphagia/change of voice	Transoral
Nisa et al. [64]	2011	F	38	8.5	Posterolateral/ventral	Dysphagia/dysphonia/dyspnea	Transoral
Monga et al. [65]	2013	M	20	2	Posterolateral/base	Lump	Transoral
Lira et al. [5]	2013	F	26	2.5	Posterior/ventral	Cervical pain	Transoral
Erkul et al. [66]	2013	M	21	3	Posterolateral/ventral	Chewing difficulty	Transoral
Jayaraman et al. [67]	2013	F	25	3	Anterolateral	Lump	Transoral
George et al. [4]	2014	M	26	4	Posterolateral/base	Dysphagia/dysphonia	Transoral
Bhola et al. [11]	2014	F	14	1.5	Anterolateral/ventral	Lump	Transoral
Moreno-Garcia et al. [68]	2014	F	13	2	Anterior/ventral	Lump	Lipsplit/mandibulotomy
Nibhoria et al. [69]	2015	F	18	1.5	Posterolateral/ventral	Lump	Transoral
Gopalakrishnan et al. [70]	2016	M	32	3	Posterolateral/ventral	Dysphagia	Transoral
Sharma and Rai [71]	2016	F	20	4	Posterolateral/ventral	Dysphagia/dysphonia	Transoral
Kavčić and Božić [72]	2016	F	20	1.3	Anterolateral/ventral/tip	Lump	Transoral
Lee et al. [73]	2016	M	28	4	Posterior/ventral	Lump	Transoral
Zain et al. [12]	2016	F	24	Not clear	Posterior	Lump	Transoral
Steffi Sharma et al.	2018	F	20	4	Posterior	Lump	Transoral
Current	2019	M	28	4	Posterior	Lump	Transoral

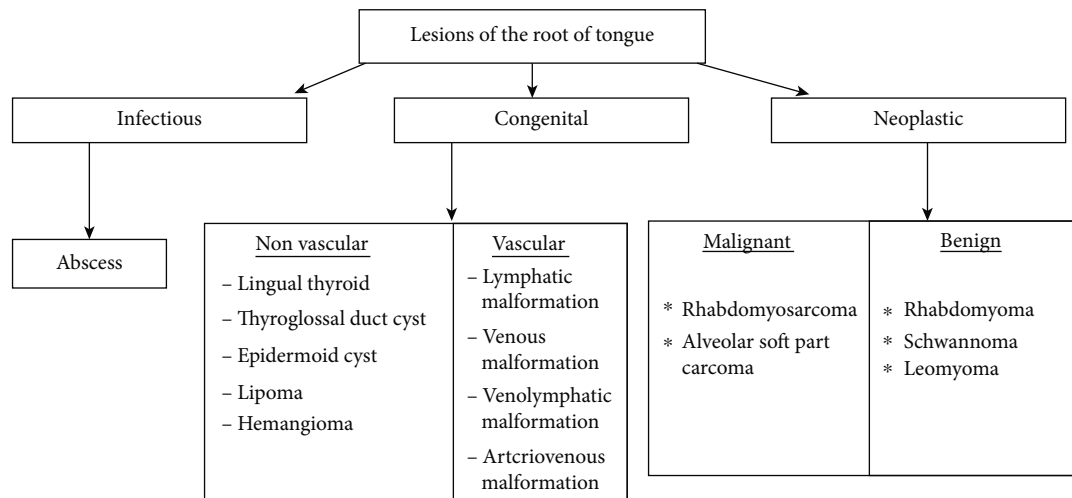


FIGURE 9: Base of the tongue lesions can be subcategorized as above.

5. Conclusions

Diagnosis of schwannoma should be considered for a smooth, painless, firm swelling in the tongue. A schwannoma of the tongue may grow large enough before producing any symptom. Total excision is the treatment of choice particularly in a young patient as it continues to grow. Most of the cases can be completely excised transorally. Total surgical excision of the lesion does not result in any recurrence.

Conflicts of Interest

The authors declare that there is no conflict of interests regarding the publication of this paper.

References

- [1] H. Harada, K. Omura, and A. Maeda, "A massive pleomorphic adenoma of the submandibular salivary gland accompanied by neurilemmomas of the neck misdiagnosed as a malignant tumor: report of case," *Journal of Oral and Maxillofacial Surgery*, vol. 59, no. 8, pp. 931–935, 2001.
- [2] R. de Bree, G. Westerveld, and L. Smelee, "Submandibular approach for excision of a large schwannoma in the base of the tongue," *European Archives of Oto-Rhino-Laryngology*, vol. 257, no. 5, pp. 283–286, 2000.
- [3] W. Nelson, T. Chuprevich, and D. Galbraith, "Enlarging tongue mass," *Journal of Oral and Maxillofacial Surgery*, vol. 56, pp. 224–227, 1988.
- [4] N. George, M. Wagh, P. Balgopal, A. Gupta, R. Sukumaran, and P. Sebastian, "Schwannoma base tongue: case report and review of literature," *The Gulf Journal of Oncology*, vol. 16, pp. 94–100, 2014.
- [5] R. B. Lira, G. Filho, G. B. Carvalho, C. A. Pinto, and L. P. Kowalski, "Lingual schwannoma: case report and review of the literature," *Acta Otorhinolaryngologica Italica*, vol. 33, no. 2, pp. 137–140, 2013.
- [6] H. Arda, O. Akdogan, N. Arda, and Y. Sarikaya, "An unusual site for an intraoral schwannoma: a case report," *American Journal of Otolaryngology*, vol. 24, no. 5, pp. 348–350, 2003.
- [7] Y. Hsu, C. Hwang, R. Hsu, F. Kuo, and C. Chien, "Schwannoma (neurilemmoma) of the tongue," *Acta Oto-Laryngologica*, vol. 126, pp. 861–865, 2009.
- [8] F. Tsushima, T. Sawai, K. Kayamori, N. Okada, and K. Omura, "Schwannoma in the floor of the mouth: a case report and clinicopathological studies of 10 cases in the oral region," *Journal of Oral and Maxillofacial Surgery, Medicine, and Pathology*, vol. 24, no. 3, pp. 175–179, 2012.
- [9] W. Gallo, M. Moss, D. Shapiro, and J. Gaul, "Neurilemmoma: review of the literature and report of five cases," *Journal of Oral Surgery*, vol. 35, no. 3, pp. 235–236, 1977.
- [10] J. Lopez and C. Ballistin, "Intraoral schwannoma: a clinicopathologic and immunohistochemical study of nine cases," *Archives d'Anatomie et de Cytologie Pathologiques*, vol. 41, no. 1, pp. 18–23, 1993.
- [11] N. Bholra, A. Jadhav, R. Borle, G. Khemka, U. Bhutekar, and S. Kumar, "Schwannoma of the tongue in a paediatric patient: a case report and 20-year review," *Case reports in dentistry*, vol. 2014, Article ID 780762, 5 pages, 2014.
- [12] Z. Badar, Z. Farooq, D. Zaccarini, and S. R. Ezhapilli, "Tongue Base Schwannoma: Differential Diagnosis and Imaging Features with a Case Presentation," *Radiology Case Reports*, vol. 11, no. 4, pp. 336–340, 2016.
- [13] E. Mercantini and C. Mopper, "Neurilemmoma of the tongue," *AMA*, vol. 79, pp. 542–544, 1959.
- [14] I. Cameron, "A case of neurilemmoma (schwannoma) of the tongue," *Oral Surgery, Oral Medicine, and Oral Pathology*, vol. 12, no. 12, pp. 1464–1467, 1959.
- [15] D. Chadwick, "Neurilemmoma of the tongue," *The Journal of Laryngology & Otology*, vol. 78, no. 10, pp. 959–962, 1964.
- [16] R. Craig, "Neurilemmoma of the tongue," *Archives of Disease in Childhood*, vol. 39, no. 205, pp. 297–298, 1964.
- [17] P. Pantazopoulos, "Schwannoma of nose, oral cavity, and pharynx," *Acta Oto-Laryngologica*, vol. 60, pp. 97–104, 2009.
- [18] D. Chhatbar, "A case of neurilemmoma of the tongue," *The Journal of Laryngology and Otology*, vol. 79, no. 2, pp. 170–174, 1965.
- [19] H. Firfer, D. Sohn, R. Heurlin, and O. Stuteville, "Neurilemmoma of the tongue," *Oral Surgery, Oral Medicine, and Oral Pathology*, vol. 21, no. 2, pp. 139–142, 1966.

- [20] J. Hatziotis and H. Aspride, "Neurilemmoma (schwannoma) of the oral cavity," *Oral surgery, Oral medicine, Oral pathology*, vol. 24, pp. 510–526, 1967.
- [21] R. Oles and F. Werthemier, "Neurilemmoma of the tongue," *The Journal of the Michigan State Dental Association*, vol. 49, pp. 7–8, 1967.
- [22] Y. Paliwal, V. Kapur, and R. Singh, "Neurilemmoma of the tongue: case report," *International Surgery*, vol. 47, no. 5, pp. 503–506, 1967.
- [23] W. Crawford, L. Korcin, and F. J. Greskovich, "Neurilemmoma of the oral cavity: report of five cases," *Journal of oral surgery*, vol. 26, pp. 651–658, 1968.
- [24] T. Das Gupta, R. Brasfield, E. Strong, and S. Hadju, "Benign solitary schwannomas (neurilemmomas)," *Cancer*, vol. 24, no. 2, pp. 355–366, 1969.
- [25] O. Bitici, "Neurilemmoma of the tongue," *The Journal of Laryngology and Otology*, vol. 83, no. 2, pp. 201–204, 1969.
- [26] S. Sinha and K. Samuel, "Neurilemmoma of tongue," *The Journal of Laryngology & Otology*, vol. 85, no. 6, pp. 623–626, 1971.
- [27] A. Monsadomi, "Neurilemmoma of the tongue," *Journal of Oral Medicine*, vol. 30, pp. 44–46, 1975.
- [28] K. Swangsilpa, J. Winther, and L. Nybroe, "Neurilemmomas in the oral cavity," *Journal of Dentistry*, vol. 4, no. 5, pp. 237–241, 1976.
- [29] R. Sharan and M. Akhtar, "Neurilemmoma of tongue," *Journal of the Indian Medical Association*, vol. 71, no. 11, pp. 290–291, 1978.
- [30] Y. Akimoto, H. Yamamoto, H. Nishimura, M. Komiya, and K. Kaneko, "Neurilemmoma in the oral cavity," *The Journal of Nihon University School of Dentistry*, vol. 29, no. 3, pp. 203–205, 1987.
- [31] C. Sira, K. Ng, T. Chia, and M. Kulkarni, "Atypical neurilemmoma of the tongue: report of two cases," *Dental Update*, vol. 29, pp. 83–85, 1988.
- [32] F. Flickinger, R. Lozano, W. Yuh, and M. Sachs, "Neurilemmoma of the tongue: MR finding," *Journal of Computer Assisted Tomography (New York, NY)*, vol. 13, no. 5, pp. 886–888, 1989.
- [33] Y. Talmi, R. Gal, Y. Finkelstein, V. Shvilli, and Y. Zohar, "Pathologic quiz case 1: benign schwannoma of tongue," *Archives of Otolaryngology - Head & Neck Surgery*, vol. 117, no. 8, pp. 926–928, 1991.
- [34] C. Gallesio and S. Berrone, "Schwannoma located in the tongue: a clinical case report," *Minerva Somatologica*, vol. 41, pp. 583–590, 1992.
- [35] J. Haring, "Case #10. Neurilemmoma," *RDH*, vol. 14, pp. 12–12, 1994.
- [36] H. Nakayama, R. Gobara, F. Shimamoto, and H. Kajihara, "Ancient schwannoma of the oral floor and ventricular portion of the tongue: a case report and review of the literature," *Japanese Journal of Clinical Oncology*, vol. 26, no. 3, pp. 185–188, 1996.
- [37] A. Dreher, R. Gutmann, and G. Grevers, "Extracranial schwannoma of the ENT region. Review of the literature with a case report of benign schwannoma of the base of the tongue," *HNO*, vol. 45, no. 6, pp. 468–471, 1997.
- [38] O. Spandow, M. Frgerlund, L. Bergmark, and L. Boquist, "Clinical and histopathological features of a large parapharyngeal neurilemmoma located at the tongue," *ORL: Journal for Otorhinolaryngology and Its Related Specialties*, vol. 61, no. 1, pp. 25–30, 1999.
- [39] R. Pfeifle, D. Baur, A. Paulino, and J. Helmen, "Schwannoma of the tongue: report of 2 cases," *Journal of Oral and Maxillofacial Surgery*, vol. 59, no. 7, pp. 802–804, 2001.
- [40] F. Cinar, S. Cinar, and G. Harman, "Schwannoma of the tip of the tongue in a child," *Plastic and Reconstructive Surgery*, vol. 114, no. 6, pp. 1657–1658, 2004.
- [41] B. Bassichis and J. McMlay, "Pedunculated neurilemmoma of the tongue base," *Otolaryngology—Head and Neck Surgery*, vol. 130, pp. 639–641, 2016.
- [42] T. Nakasato, Y. Kamada, S. Ehara, and Y. Miura, "Multilobular neurilemmoma of the tongue in a child," *AJNR. American Journal of Neuroradiology*, vol. 26, no. 2, pp. 421–423, 2005.
- [43] K. Hwang, S. Kim, S. Ahn, and S. Lee, "Neurilemmoma of the tongue," *The Journal of Craniofacial Surgery*, vol. 16, no. 5, pp. 859–861, 2005.
- [44] P. Lopez-Jornet and A. Bermejo-Fenoll, "Neurilemmoma of the tongue," *Oral Oncology Extra*, vol. 41, no. 7, pp. 154–157, 2005.
- [45] M. Vafiadis, A. Fiska, M. Panopoulou, and D. Assimakopoulou, "A clinical case report of a schwannoma on the tip of the tongue," *B-ENT*, vol. 1, no. 4, pp. 201–204, 2005.
- [46] R. Bansal, P. Trivedi, and S. Patel, "Schwannoma of the tongue," *Oral Oncology Extra*, vol. 41, no. 2, pp. 15–17, 2005.
- [47] Y. Ying, L. Zimmer, and E. Myers, "Base of tongue schwannoma: a case report," *Laryngoscope*, vol. 116, no. 7, pp. 1284–1287, 2006.
- [48] M. Enoz, Y. Suoglu, and R. Ilhan, "Lingual schwannoma," *Journal of Cancer Research and Therapeutics*, vol. 2, no. 2, pp. 76–78, 2006.
- [49] H. Mehrzad, R. Persaud, N. Papadimitriou, S. Kaniyur, and G. Mochloilis, "Schwannoma of tongue base treated with transoral carbon dioxide laser," *Lasers in Medical Science*, vol. 21, no. 4, pp. 235–237, 2006.
- [50] K. Batra, A. Rai, N. Chaudhary, and S. Topno, "Two cases of neurilemmoma of the tongue," *Ear, Nose & Throat Journal*, vol. 86, pp. 679–681, 2019.
- [51] F. Ballesteros, I. Vilaseca, J. Blanch, A. Gaspa, and M. Bernal-Sprekelsen, "Base of tongue neurilemmoma: excision by transoral laser microsurgery," *Acta Oto-Laryngologica*, vol. 127, pp. 1005–1007, 2009.
- [52] R. Sawhney, M. Carron, and R. Mathog, "Tongue base schwannoma: report, review, and unique surgical approach," *American Journal of Otolaryngology*, vol. 29, no. 2, pp. 119–122, 2008.
- [53] D. Sethi, A. Sethi, S. Nigam, and A. Agarwal, "Schwannoma of oral tongue: a rare benign neoplasm," *The International Journal of Head and Neck Surgery*, vol. 3, no. 1, p. 8496, 2008.
- [54] L. Pereira, P. Pereira, J. P. dos Santos, V. Reis Filho, P. R. Dominguet, and A. A. Pereira, "Lingual schwannoma involving the posterior lateral border of the tongue in a young individual: case report," *The Journal of Clinical Pediatric Dentistry*, vol. 33, no. 1, pp. 59–62, 2008.
- [55] M. Cohen and M. Wang, "Schwannoma of the tongue: two case reports and review of the literature," *European Archives of Oto-Rhino-Laryngology*, vol. 266, no. 11, pp. 1823–1829, 2009.
- [56] P. Gupta, A. Garg, K. Dhingra, D. Jain, K. Kohli, and N. Khurana, "Schwannoma tongue: a rare entity," *ANZ Journal of Surgery*, vol. 79, no. 1–2, pp. 93–94, 2009.
- [57] K. Mardanpour and M. Rahbar, "Lingual schwannoma: a case report," *IRCMJ*, vol. 11, pp. 454–456, 2009.

- [58] C. Karaca, T. Habesoglu, B. Naiboglu et al., “Schwannoma of the tongue in a child,” *American Journal of Otolaryngology*, vol. 31, pp. 46–48, 2010.
- [59] T. Cigdem, E. Tulay, N. Baris et al., “Schwannoma of the tongue in a child,” *American Journal of Otolaryngology and Head and Neck Surgery*, vol. 31, pp. 46–48, 2010.
- [60] B. Jeffcoat, K. Pitman, A. Brown, and M. Baliga, “Schwannoma of the oral tongue,” *Laryngoscope*, vol. 120, Suppl 4, p. S154, 2010.
- [61] G. Naidu and S. Sinha, “Schwannoma of the tongue: an unusual presentation in a child,” *IJDR*, vol. 21, no. 3, pp. 457–459, 2010.
- [62] I. Lukšić, D. Müller, M. Virag, S. Manojlović, and K. Ostović, “Schwannoma of the tongue in a child,” *Journal of Cranio-Maxillo-Facial Surgery*, vol. 39, no. 6, pp. 441–444, 2011.
- [63] U. Batra, G. Usha, and A. Gogia, “Anesthetic management of schwannoma of the base of the tongue,” *Journal of anaesthesiology, clinical pharmacology*, vol. 27, pp. 241–243, 2011.
- [64] L. Nisa, T. von Büren, A. Tiab, and R. Giger, “Giant plexiform schwannoma of the tongue,” *Case Reports in Otolaryngology*, vol. 2011, 3 pages, 2011.
- [65] S. Monga, J. Malik, and A. Sharma, “Schwannoma tongue,” *Journal of Case Reports*, vol. 3, no. 2, pp. 220–222, 2013.
- [66] E. Erkul, H. Cıncık, A. Haholu, E. Cekin, and A. Güngör, “Schwannoma of the tongue: a report of two cases and review,” *Gulhane Medical Journal*, vol. 55, 2013.
- [67] V. Jayaraman, B. Balasubramanian, and R. Senthivelu, “Schwannoma of the tongue—a rare clinical entity,” *IJDSR*, vol. 1, pp. 53–55, 2013.
- [68] C. Moreno-García, M. A. Pons-García, R. González-García, and F. Monje-Gil, “Schwannoma of tongue,” *Journal of maxillofacial and oral surgery*, vol. 13, no. 2, pp. 217–221, 2014.
- [69] S. Nibhoria, K. Tiwana, R. Phutela, and J. Kaur, “Schwannoma of tongue: a rare case presentation with review of literature,” *IJSS*, vol. 3, pp. 147–149, 2015.
- [70] S. Gopalakrishnan, N. Jayaraman, and S. A. L. Albina, “Schwannoma over tongue base—case report and review,” *Online Journal of Otolaryngology*, vol. 6, pp. 1–7, 2016.
- [71] S. Sharma and G. Rai, “Schwannoma (neurilemmoma) on the base of the tongue: a rare clinical case,” *The American journal of case reports*, vol. 17, pp. 203–206, 2016.
- [72] J. Kavčič and M. Božič, “Schwannoma of the tongue,” *BML Case Reports*, vol. 10, 2016.
- [73] H. Lee, S. Won, J. Kin, and S. Woo, “A case of schwannoma of the tongue base,” *Korean Journal of Otorhinolaryngology-Head and Neck Surgery*, vol. 59, no. 3, pp. 229–232, 2016.