

## Case Report

# Lung Transplantation in a Patient with COPA Syndrome

Jorge M. Mallea , Anna Kornafeld , Andras Khoor , and David B. Erasmus 

Mayo Clinic, 4500 San Pablo Rd S, Jacksonville, FL 32224, USA

Correspondence should be addressed to Jorge M. Mallea; [mallea.jorge@mayo.edu](mailto:mallea.jorge@mayo.edu)

Received 16 August 2019; Accepted 21 March 2020; Published 1 April 2020

Academic Editor: Federica Meloni

Copyright © 2020 Jorge M. Mallea et al. This is an open access article distributed under the Creative Commons Attribution License, which permits unrestricted use, distribution, and reproduction in any medium, provided the original work is properly cited.

COPA syndrome is a newly discovered, rare genetic autoimmune disorder, which can affect the lungs, joints, and kidneys. It is difficult to recognize, and the survival benefit of lung transplantation for these patients is not yet known. We present a case of a 24-year-old woman who received bilateral lung transplant for COPA syndrome. At 15 months posttransplant, her pulmonary function is stable with no episodes of acute cellular- or antibody-mediated rejection and no evidence of disease recurrence.

## 1. Introduction

COPA syndrome was first reported in 2015 [1]. It is a rare, genetic autoinflammatory disorder, which can affect the lungs, joints, and kidneys. It is caused by mutations in the gene of coatamer subunit  $\alpha$ , a subunit of coat protein complex I (COPI). COPI is a carrier complex involved in the intracellular retrograde protein transport from Golgi to endoplasmic reticulum. The product of the mutant gene triggers processes that play a role in developing autoimmunity [1]. Since it is a rare disease, COPA syndrome is difficult to recognize. The following common pulmonary findings have been described in genetically confirmed cases: cysts, follicular bronchiolitis, and diffuse alveolar hemorrhage. Other common characteristics include positive family history, early age onset, COPA syndrome in another family member, arthritis, nephritis, and positivity for antineutrophil cytoplasmic antibody (ANCA), antinuclear antibody (ANA), or rheumatoid factor (RF) [2].

## 2. Case Presentation

A 24-year-old woman received bilateral lung transplant for COPA syndrome. Manifestations of her COPA syndrome included arthritis, biopsy-confirmed immune-mediated kidney disease, antineutrophil cytoplasmic antibody (ANCA) positivity, interstitial lung disease, diffuse alveolar hemor-

rhage, and progressive respiratory failure leading to mechanical ventilator support. Chest computed tomography demonstrated extensive cystic changes in the lungs, diffuse coarse reticular interstitial thickening, and ground glass opacities (Figure 1). Pulmonary function tests showed a restrictive pattern with decreased DLCO. She received rituximab and plasmapheresis in the perioperative period and induction immunosuppression with thymoglobulin. Histologic sections of the explanted lungs showed a relatively uniform fibrosing interstitial pneumonia (nonusual interstitial pneumonia pattern) with honeycomb change and emphysema (Figure 2). Organizing lung injury and patchy alveolar hemorrhage with hemosiderin-laden macrophages were noted, but capillaritis was not seen.

The postoperative course was complicated by neutropenic fever, cytomegalovirus viremia, bilateral lymphocytic pleural effusions, and persisting leukopenia. A year after transplant, she had no respiratory symptoms, but testing confirmed severe gastroesophageal reflux disease (GERD). She was successfully treated with laparoscopic Nissen fundoplication. At 15 months posttransplant, her pulmonary function is stable, with no episodes of acute cellular- or antibody-mediated rejection and no evidence of disease recurrence. She is maintained on an immunosuppression regimen that includes prednisone, tacrolimus, and intravenous immunoglobulin.

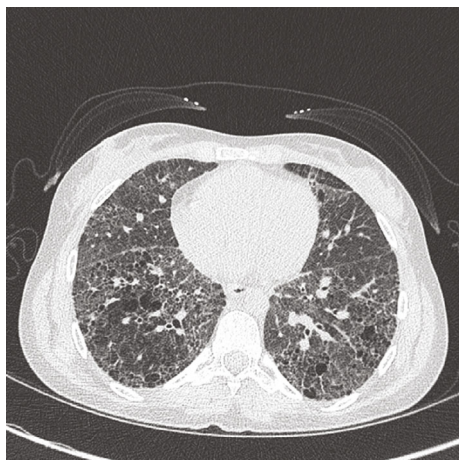

FIGURE 1: Chest computed tomography of the patient's native lungs demonstrating cystic changes, diffuse coarse reticular interstitial thickening with associated ground glass opacities.

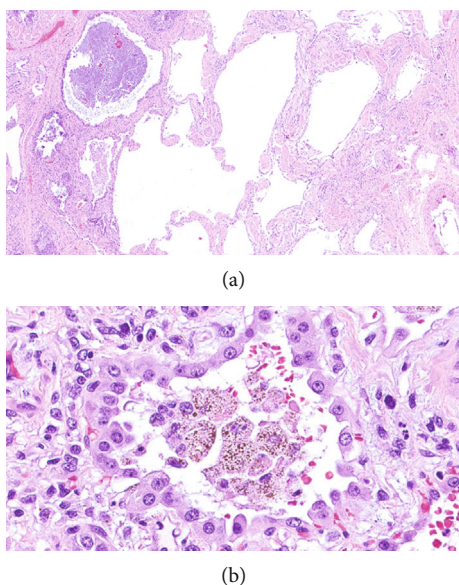


FIGURE 2: Histologic sections of the explanted (native) lungs show (a) fibrosing interstitial pneumonia with airspace enlargement (hematoxylin-eosin, original magnification 30x) and (b) alveolar hemorrhage with hemosiderin-laden macrophages and reactive type 2 cells (hematoxylin-eosin, original magnification 400x).

### 3. Discussion

The survival benefit of lung transplantation for patients with COPA syndrome is not yet known. In general, immune dysregulation associated with autoimmune disorders may be a reason for concern. According to a recent study, patients who underwent lung transplantation for nonscleroderma connective tissue-related lung disease are not more likely to develop acute rejection or bronchiolitis obliterans syndrome compared with IPF [3]. To our knowledge, only three other adult COPA syndrome patients have received lung transplants [4, 5]. One had a “near standard” posttransplant sur-

vival; survival of the other two patients (mother and adult son) has not been reported. Our patient is doing well 15 months after transplantation, but an international registry is needed to clarify the outcome. In the meantime, transplantation of COPA syndrome patients requires careful consideration.

### Abbreviations

ANA: Antinuclear antibody  
 ANCA: Antineutrophil cytoplasmic antibody  
 COPA: Coatomer subunit alpha  
 COPI: Coat protein complex I  
 DLCO: Diffusing capacity of the lungs for carbon monoxide  
 GERD: Gastroesophageal reflux disease  
 RF: Rheumatoid factor.

### Conflicts of Interest

The authors have no conflicts of interest to disclose.

### References

- [1] Baylor-Hopkins Center for Mendelian Genomics, L. B. Watkin, B. Jessen et al., “\_COPA\_ mutations impair ER-Golgi transport and cause hereditary autoimmune-mediated lung disease and arthritis,” *Nature Genetics*, vol. 47, no. 6, pp. 654–660, 2015.
- [2] J. L. Tsui, O. A. Estrada, Z. Deng et al., “Analysis of pulmonary features and treatment approaches in the COPA syndrome,” *ERJ Open Research*, vol. 4, no. 2, article 00017, 2018.
- [3] A. M. Courtwright, S. El-Chemaly, P. F. Dellaripa, and H. J. Goldberg, “Survival and outcomes after lung transplantation for non-scleroderma connective tissue-related interstitial lung disease,” *The Journal of Heart and Lung Transplantation*, vol. 36, no. 7, pp. 763–769, 2017.
- [4] B. O. Jensson, S. Hansdottir, G. A. Arnadottir et al., “COPA syndrome in an Icelandic family caused by a recurrent missense mutation in COPA,” *BMC Medical Genetics*, vol. 18, no. 1, p. 129, 2017.
- [5] T. J. Vece, L. B. Watkin, S. Nicholas et al., “Copa syndrome: a novel autosomal dominant immune dysregulatory disease,” *Journal of Clinical Immunology*, vol. 36, no. 4, pp. 377–387, 2016.