

Motor Deficits Are Produced By Removing Some Cortical Transplants Grafted Into Injured Sensorimotor Cortex of Neonatal Rats

Rick Sandor^{1,3}, Manuel F. Gonzalez^{1,3}, Michael Moseley², Frank R. Sharp^{1,3}

Departments of ¹Neurology and ²Radiology, University of California at San Francisco, and the ³Veterans Affairs Medical Center, San Francisco, California 94121, U.S.A.

ABSTRACT

Fetal frontal cortex was transplanted into cavities formed in the right motor cortex of neonatal rats. As adults, the animals were trained to press two levers in rapid succession with their left forelimb to receive food rewards. Once they had reached an optimal level of performance, the effect of removing their transplants was assessed. Surgical removal of transplants significantly impaired the performance of 2 of 4 subjects. Placing a cross-strain skin graft to induce the immunological rejection of the transplants produced a behavioral deficit in 1 of 2 subjects with complete transplant removal. Skin grafts produced no behavioral effects in four subjects that had surviving transplants. Since the motor deficits produced by transplant removal resembled those observed following the removal of normal motor cortex, we propose that these three transplants functioned within the host brain.

Histology showed that the procedures used to remove cortical grafts did not injure any host brains. Therefore, host brain damage is unlikely to account for the behavioral deterioration that followed transplant removals.

Key words: Fetal cortical transplant; rat motor cortex lesion; forelimb motor deficit

INTRODUCTION

While fetal cortical grafts survive and establish connections with host brains /5-8,11-13,18/, many questions regarding their function remain unanswered. The cognitive deficits and behavioral impairments produced by bifrontal cortical lesions /23/ or basal forebrain lesions /1,36/ in mature rats are partially reversed by fetal grafts. Also, though the motor deficits induced by cortical lesions in mature subjects may not be reversed by cortical grafts /10,22,23/, motor deficits produced by frontal cortex injury of neonatal rats are ameliorated by transplanting dissociated fetal cortical cells /27/.

In this study we transplanted fetal cortex into injured right motor cortex of neonatal rats. Once hosts matured, we examined whether removing the grafts affected motor performance of their

Reprint address:
Frank R. Sharp
VA Medical Center
Neurology Service (127)
4150 Clement Street
San Francisco, CA 94121, U.S.A.

left forelimbs. To accomplish this, rats were trained to press two levers in fast succession /16/. The time it took them to press the two levers, called interresponse time (IRT), was quantified. In normal rats, a lesion in contralateral forelimb motor cortex acutely and chronically increases IRTs /16/. Once the rats in this study reached optimal performance, their transplants were removed surgically or they received cross-strain skin grafts to induce immunological rejection of their transplants /2,9,14,26,35/. Transplant removal produced a significant deterioration in the IRTs in three subjects. This suggests that these transplants functioned during the performance of the present motor task in a way analogous to normal motor cortical tissue.

MATERIAL AND METHODS

Animals

Thirty six neonatal Long-Evans rats served as hosts. Animals were weaned at 3 weeks of age and given standard Purina rat chow and water ad libitum. Training commenced at 6 - 8 weeks of age. At this time, subjects were given enough food to maintain them at 80% of their free-feeding body weight. Though on a diet, host rats steadily gained weight and appeared healthy throughout the experiment.

Transplantation surgery

One day old host rats were anesthetized with hypothermia. The scalp was incised, and a 1.5 mm per side square bone flap was made over the right frontal cortex, centered 0.3 mm anterior to bregma and 2 mm lateral to the midline. The underlying cortex, which corresponds in location to the forelimb motor cortex in the adult rat, was removed down to the white matter with a syringe and blunt needle. After bleeding was controlled, the cavity was filled with Gelfoam, the overlying skull was folded back into place and the skin was sutured.

At 7 days of age, host subjects were re-anesthetized with hypothermia. The cavities were re-opened and the Gelfoam was removed. E17-E18 day fetuses were removed individually from anesthetized, pregnant mothers. The fetal brain was exposed, and a slab of frontal cortex approximately 2 mm² was removed with a scalpel

and placed into the cavities of the host animals /17,18,28,29,31/. The skull flaps were then closed, and the scalps sutured. Half of the subjects (#1-18) received transplants from Long-Evans donors and the other half (#19-36) from Sprague-Dawley donors.

Transplant survival verification

At six weeks of age, when training began, the 36 host subjects were anesthetized with ketamine (80 mg/kg) and xylazine (20 mg/kg) i.p. The cavities were carefully opened. Twelve rats that had large, visually apparent transplants and a rat with an obvious large cavity were selected for the study.

Four of the 12 subjects were re-anesthetized and Magnetic Resonance Imaging (MRI) scans of their heads were obtained. MRIs were performed on a General Electric CSI imaging spectrometer operating at 2.0 Tesla (85.6 Mhz proton resonance frequency). A standard spin-echo 2DFT spin-warp proton imaging sequence yielded single slices from 2 or 4 phase-cycled image excitations. Slice selection in each image was 2 mm with 128 or 256 phase-encoding cycles x 512 point complex readout raw data matrices. For T1 weighted images, the repetition time (TR) was 400 msec and the echo time (TE) was 16 msec. For T2 weighted images the TR was 2000 msec and the TE was 60 msec. During imaging rats were positioned supine in an imaging coil of the low-pass birdcage resonator design /19/ with an inner diameter of 5 cm. Because of limited access to the MRI scanner, scans were limited to subjects that were to receive skin grafts to produce immunological rejection of transplants.

Apparatus

Rats were trained in modified rodent operant chambers equipped with an automatic feeder (Lafayette Instruments, Lafayette, IN). To the left of the feeder there were two levers with smooth steel balls, 8 mm in diameter, attached to their ends /16/. A metal partition between the levers prevented rats from pressing both levers at once.

Operant chambers were interfaced to a Compaq computer via a LVB interface (Med Associates, Fairfield, VT). OPN operant software was used to monitor response times and

number of lever presses, to deliver food pellet reinforcements, and to store data /16/.

Training

Rats were trained to use their left forelimb to press the right lever and then the left lever using successive approximation operant techniques /16/. At first, rats had unlimited time to perform this task and receive a reward. Later, responses were rewarded only if the time between lever presses, called the interresponse time (IRT), was less than a fixed interval. These time intervals were slowly decreased to force the rats to perform the task as quickly as possible. When a rat's daily average IRT was 2 sec or less, unwanted behaviors, such as the use of the right paw or snout, were shaped out by withholding reinforcements or by administering low amperage shocks (Master Shocker, Lafayette Inst.). Rats were deemed trained once, in a typical lever session, their IRTs were \leq 600 msec and received between 50 and 80 rewards.

Transplant removal

Rats were judged to have reached an optimal level of performance when two criteria were met. First, for a month's period a subject's daily IRTs were within 20% of its fastest score. Second, during this period the slope of the regression line of its daily IRTs was not significantly different from zero. These criteria were reached when rats were between 6 and 8 months old.

Once optimal performance was attained, sham operations were performed in all subjects. All subjects were anesthetized with ketamine (80 mg/kg) and xylazine (20 mg/kg) i.p. Subjects that were to have their transplants removed surgically had their scalp incised, their skulls scraped, and their skin sutured. Subjects that were to receive skin grafts were given a 20 mm long skin incision on their mid-back and sutured. The day after sham surgery, subjects were returned to their usual testing schedule. After a delay of at least one week, transplant removal was attempted using two methods.

Subjects #5, 7, and 13 had their grafts removed surgically. They were re-anesthetized and placed in a stereotaxic frame. Their scalps were incised and the skull overlying the transplant was thinned with a drill and opened

using a scalpel blade. After the transplants' edges were identified, an incision was made on the transplant side of this border to avoid host cortical injury. The inferior surface of the transplant was cut and the transplant removed with a spatula. The excised tissue was frozen in 2-methyl butane at -20°C . Following control of bleeding, the bone flap was closed and the incision sutured. Testing sessions were resumed the next day.

Subjects #19, 22, 23, 27, 30, and 33, received cross strain skin grafts in an attempt to produce immunological rejection of their transplants /2,9,14,35/. Hosts were re-anesthetized, and a 200 mm² (1 x 2 cm) portion of skin was removed next to the sham incision site. An analogous piece of skin from donor adult, anesthetized Sprague-Dawley rats (250 gm) was sutured in this place. Testing resumed the next day. Rat #31, known not to have a transplant following MRI imaging (Fig. 1C,D), also received a skin graft to serve as a control for the nonspecific effects of skin graft rejection.

An MRI scan performed in rat #19 six weeks after receiving a skin graft revealed the survival of a large cortical transplant (Fig. 1A,B). This subject was then re-anesthetized and its transplant removed surgically as described above.

Histology

At the conclusion of behavioral testing all host rats were deeply anesthetized and perfused through the heart with 4% paraformaldehyde in 0.1M phosphate buffer (pH 7.4). The brains were removed, placed in 10% sucrose phosphate buffer overnight, and 20 μm sections cut on a cryostat at -20°C . Excised transplants were also cut in a cryostat in 20 μm sections. All sections were picked up onto cover slips and air dried. Alternate sections were stained for cresyl echt violet (Nissl) and hematoxylin and eosin (H&E).

Data analysis

Analysis of variance with repeated measurements tests were performed to assess the significance of differences between daily IRTs of the baseline, sham lesion, or transplant removal conditions. Separate tests were done for animals whose transplants were removed surgically or received skin grafts. Also, the results

of individual subjects were analyzed using Kruskal-Wallis analyses of variance by ranks, and Kruskal-Wallis tests for multiple comparisons between treatments.

RESULTS

Rats varied in their ability to learn the bar pressing task. It took them 8 to 12 weeks to learn

to press alternate bars, and another 8 to 16 weeks to reach optimal performance. Twelve large transplants survived as documented by direct visual observation, MRI imaging (Fig. 1), and histology. Three rats with surviving transplants failed to reach the performance criteria and were eliminated from the study. Consequently, 9 rats, plus an additional rat (#31), known not to have a graft, remained in the study.

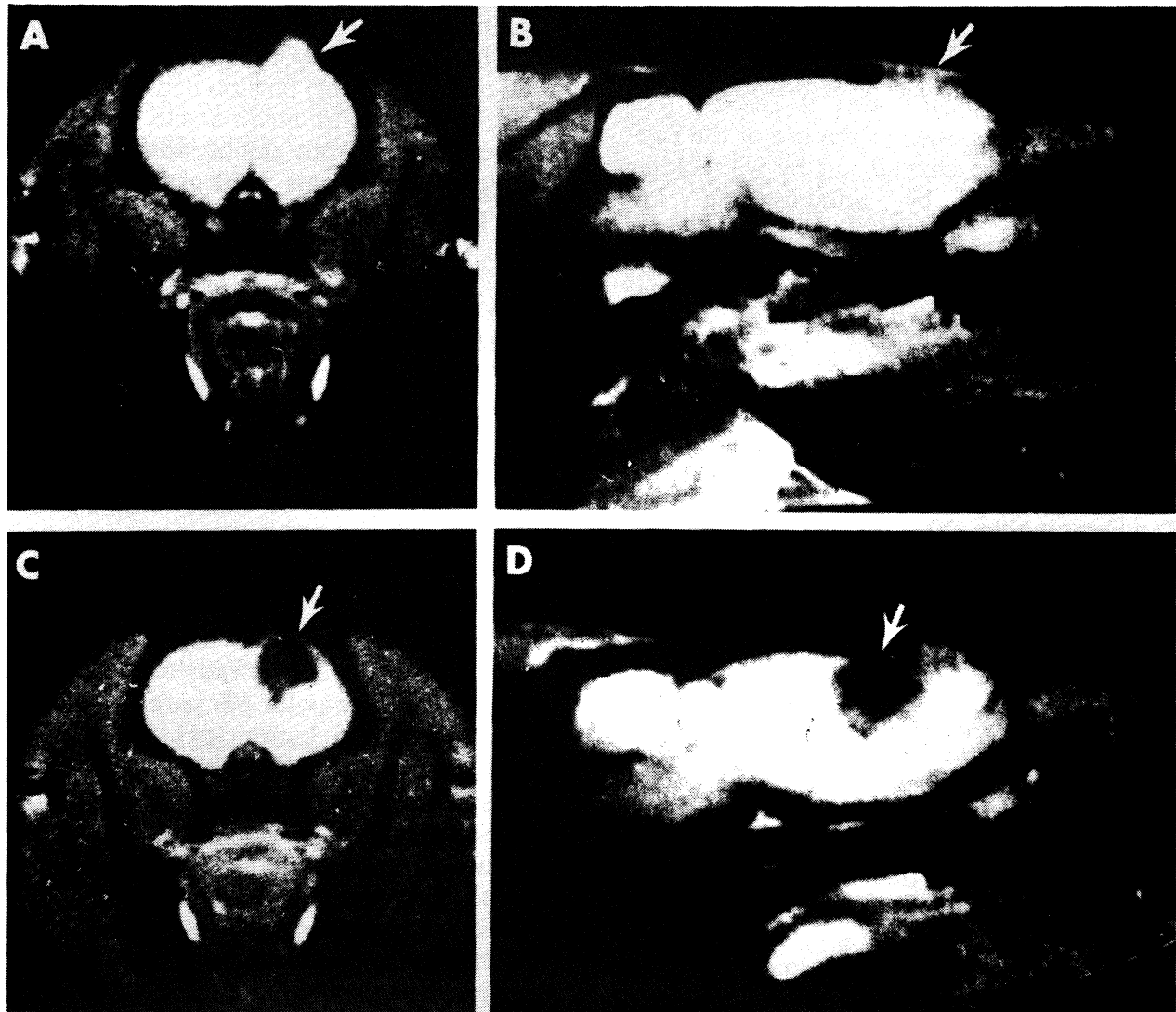


Fig. 1: Magnetic Resonance Imaging (MRI) scans of rat brains with (A,B) and without (C,D) transplants. MRI coronal (A,C) and sagittal (B,D) scans showed the size and location of surviving grafts or cavities. (A and B) MRI scan of subject #19 showing the presence of a transplant (arrows) 7 weeks after a skin graft was performed to promote its immunological rejection. This transplant was histologically verified following surgical removal (Fig. 5C,D). (C and D) MRI scans of subject #33 showing a region of CSF density (white arrows) representing a cavity in the brain without evidence of a surviving transplant 8 weeks following a skin graft.

Sham lesions

Overall, sham surgeries had no effect on the subjects' IRTs (Figs. 2-4; Table 1). The IRTs of many subjects following sham surgical removal of transplants (Figs. 2,3; Table 1) or sham skin grafts (Fig. 3; Table 1) were shorter than during the previous month's baseline. However, analysis

of variance tests revealed that the overall decreases of 6.8% (370 to 345 msec) and 12.1% (341 to 304 msec), respectively, were not statistically significant. Also, Kruskal-Wallis tests showed that the changes in the IRTs of individual subjects following sham lesions never reached statistical significance (Table 1).

TABLE 1

MEAN DAILY INTERRESPONSE TIMES (in msec ± S.E.M.s) DURING BASELINE CONDITION, AND FOLLOWING SHAM LESIONS, SURGICAL LESIONS OR SKIN GRAFTS

Rat #	Baseline	Sham Lesion	Surgical lesion or 1st month	Skin graft	Surgical lesion or 2nd month	Skin graft
SURGICAL LESIONS						
5	527.2 ± 7.6	534.0 ± 12.3	549.7 ± 5.5			
7**	273.6 ± 5.3	273.7 ± 4.4	333.0 ± 18.3 [†]		313.7 ± 9.9 ^{†,‡}	
13**	292.8 ± 9.7	287.5 ± 9.7	249.7 ± 7.7 ^{††,‡}			
19**	387.7 ± 19.3	287.5 ± 21.8	600.3 ± 44.9 ^{†,‡‡}			
Means	370.3 ± 10.5	345.6 ± 12.1	433.1 ± 19.1			
SKIN GRAFTS						
19**	387.7 ± 19.3	287.5 ± 21.8	293.3 ± 5.6 [†]			
22	225.9 ± 9.3	221.2 ± 16.0	238.9 ± 4.5		229.7 ± 4.6	
23	301.5 ± 15.0	279.5 ± 32.9	307.4 ± 7.3			
27	243.2 ± 10.9	205.7 ± 6.8	217.2 ± 5.0			
30**	453.2 ± 9.6	394.4 ± 12.1	319.1 ± 6.4 ^{††,‡‡}			
33**	402.0 ± 5.0	382.2 ± 10.8	393.2 ± 18.8		477.7 ± 5.1 ^{††,‡‡}	
Means	335.6 ± 11.5	295.1 ± 16.7	294.8 ± 7.9			
31**, [§]	370.3 ± 5.2	356.2 ± 6.5	337.0 ± 4.7 ^{††}			

Subjects in which experimental conditions differed significantly from each other are indicated by *s (* P < 0.05, ** P < 0.01). †s indicate means significantly different from baseline († P < 0.05, †† P < 0.01) and ‡s indicate means significantly different from sham lesion (‡ P < 0.05, ‡‡ P < 0.01). Comparisons were done using Kruskal-Wallis tests.

§ Subject 31 did not have a surviving graft.

Nevertheless, the small decreases in IRT values after sham lesions suggest that the motor performance of several subjects continued to improve below baseline levels.

Skin grafts

During the first month following skin grafting the IRTs of 4 of six rats (#22, 23, 27, and 33) were basically unchanged compared to baseline values (Fig. 2; Table 1). The IRTs of the remaining 2 subjects (#19 and 30) decreased significantly (Fig. 2; Table 1), indicating an improvement in their motor performance. Therefore, none of the subjects showed evidence of behavioral deterioration during the first month following skin grafting (Fig. 2; Table 1).

The basis for tissue identification from MRI images is believed to be due to inherent differences in the spin-lattice (T1) and spin-spin (T2) relaxation times of gray matter, white matter, and CSF [19]. The images obtained clearly depicted surviving grafts or cavities (Fig. 1), and were used to follow transplants' condition following skin grafts. Five or six weeks following skin grafts, cortical transplants were clearly visible within some subjects (Rat #19, Fig. 1A,B), but had virtually disappeared in others (Rat #30, Fig. 1C,D). Three subjects (#23, 27, 30) were sacrificed 5-6 weeks following skin grafts. Their motor performance during the experiment did not correlate with either their MRI images, or the histology of their brains. Two of the remaining subjects, rats #22, which

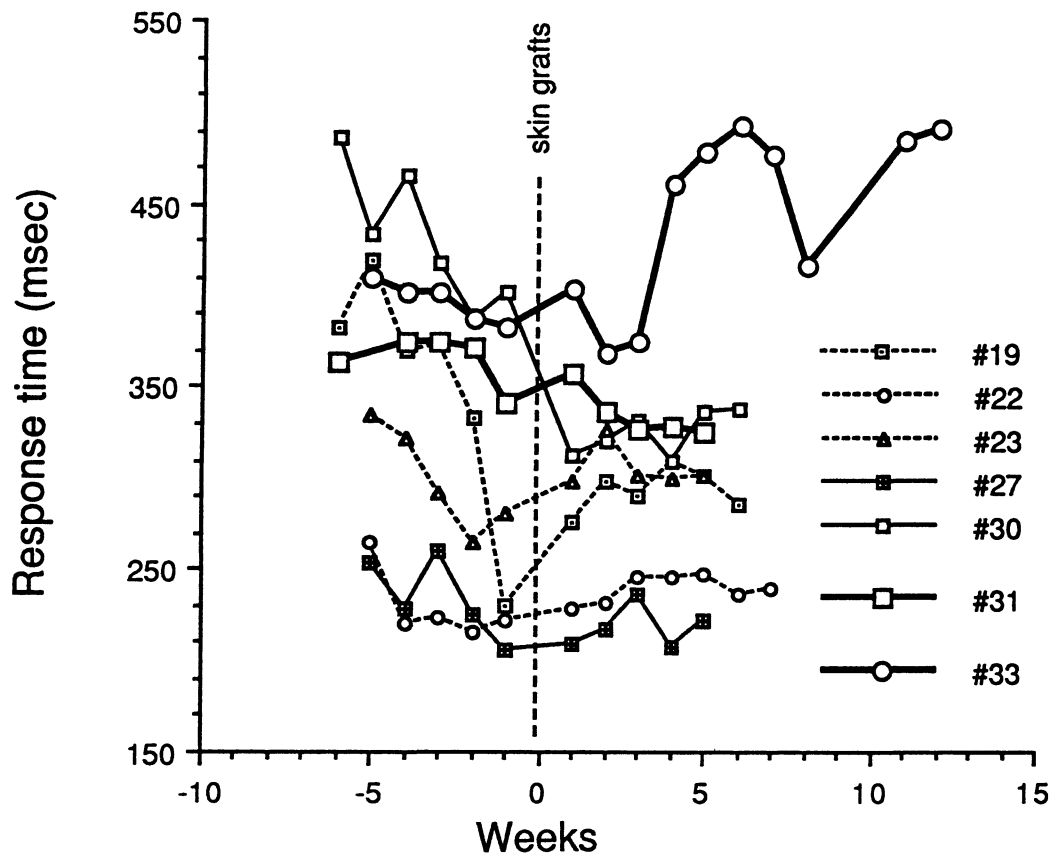


Fig. 2: Plots of motor performance of rats before and after receiving skin grafts. Data points in this and following figures represent weekly averages of daily IRTs. Points to the left of the vertical dotted line represent values of the baseline and sham lesion conditions. In subjects #22, 23, 27 and 33 the sham lesions were performed one week prior to the skin graft; and in subjects #19, 30 and 31 sham lesions were performed two weeks before the skin graft. All subjects had large transplants at 6 weeks of age, except #31 (plotted using large squares) which did not have a transplant. Several subjects exhibited reductions in IRT values following skin grafts, but only #33 (plotted using large circles) exhibited a deterioration in performance that started 4 weeks after the skin graft.

had exhibited very steady motor performance, and #33, which gave signs of motor performance deterioration, continued to be tested. The remaining rat (#19) had a large cortical graft revealed by a T1 weighted MRI scan 6 weeks after receiving a skin graft (Fig. 1A,B). This subject was anesthetized, and its transplant surgically removed. This result is described in a section below.

The IRTs of subject #22 remained unchanged during the first and second months following skin grafting (Fig. 2; Table 1). However, the IRTs of subject #33 (Fig. 2; Table 1) significantly increased starting on week 4 following the skin graft. This impairment of motor behavior persisted during the following eight weeks of testing (Fig. 2; Table 1).

An analysis of variance on the combined data of all six subjects failed to show that skin grafts

produced significant changes in performance. However, nonparametric test showed that the improvements in performance of rats #19 and 30 of the first month following skin grafts, and the increases in IRTs seen in rat #33 during the second and third months following skin grafting were statistically significant (Table 1).

Rat #31, the control rat without a surviving graft, showed a small but significant decrease in IRTs following skin grafting (Fig. 3; Table 1), suggesting that a skin graft by itself does not adversely affect forelimb motor function.

Surgical lesions

The IRTs of 2 of 3 rats that had their transplants removed surgically (#5 and 13) did not increase following surgery. Rat #5's performance remained stable (Fig. 3; Table 1),

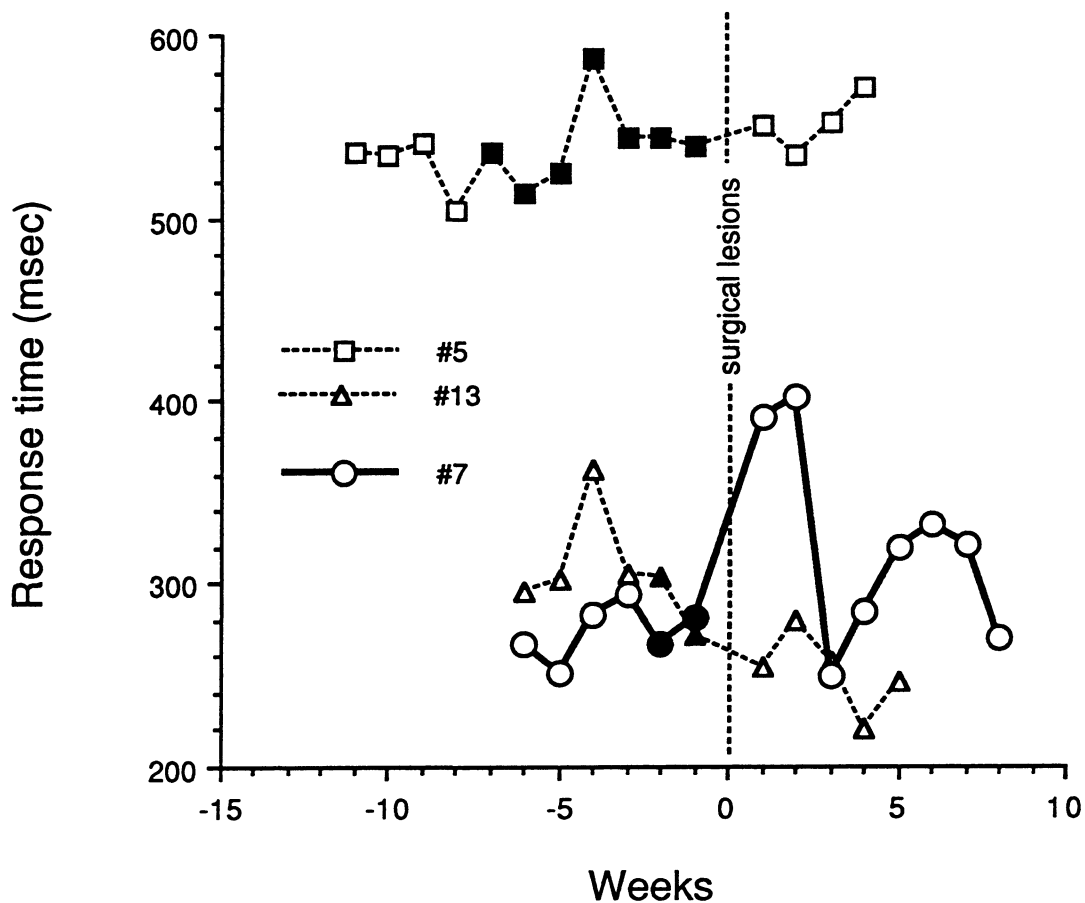


Fig. 3: Plots of motor performance of rats before and after they had their grafts removed surgically. Data points to the left of the vertical dotted line represent values of the baseline and sham lesion conditions. Filled symbols indicate values following sham lesions. Only subject #7 exhibited a deterioration in performance following the surgical removal of its transplant.

while rat #13 exhibited a small but statistically significant reduction in its IRTs following surgical lesion (Fig. 3; Table 1) which resembled the reductions seen in some subjects following skin grafts (Fig. 3; Table 1).

Conversely, rat #7 had a marked deterioration in motor performance, manifested by an increase in IRTs, during the first two weeks that followed surgical removal of the transplant (Fig. 3; Table 1). The performance of this subject oscillated over the next six weeks but its overall performance was worse than pre-operative levels (Fig. 3; Table 1). Rat #19 had its transplant surgically removed six weeks following skin grafting when a MRI scan showed what appeared to be an intact transplant (Fig. 1A). Following the surgical removal of its transplant, subject #19 had a marked increase in its IRTs (Fig. 4) similar to that of subject #7. This

deterioration in motor performance persisted for over a month (Fig. 4; Table 1).

An analysis of variance on the combined results of these four subjects did not show a statistically significant effect of surgical transplant removal. However, nonparametric tests on data of individual subjects revealed that the increases of IRTs of rats #7 and 19 were statistically significant (Table 1) when compared to baseline and sham values. In both cases, surgical removal of transplants produced a marked deterioration in behavioral performance that slowly improved over time (Figs. 3,4). This contrasts to subject #33, whose performance was normal immediately following skin grafting and deteriorated many weeks later, presumably following the immunological rejection and removal of the transplant (Fig. 2).

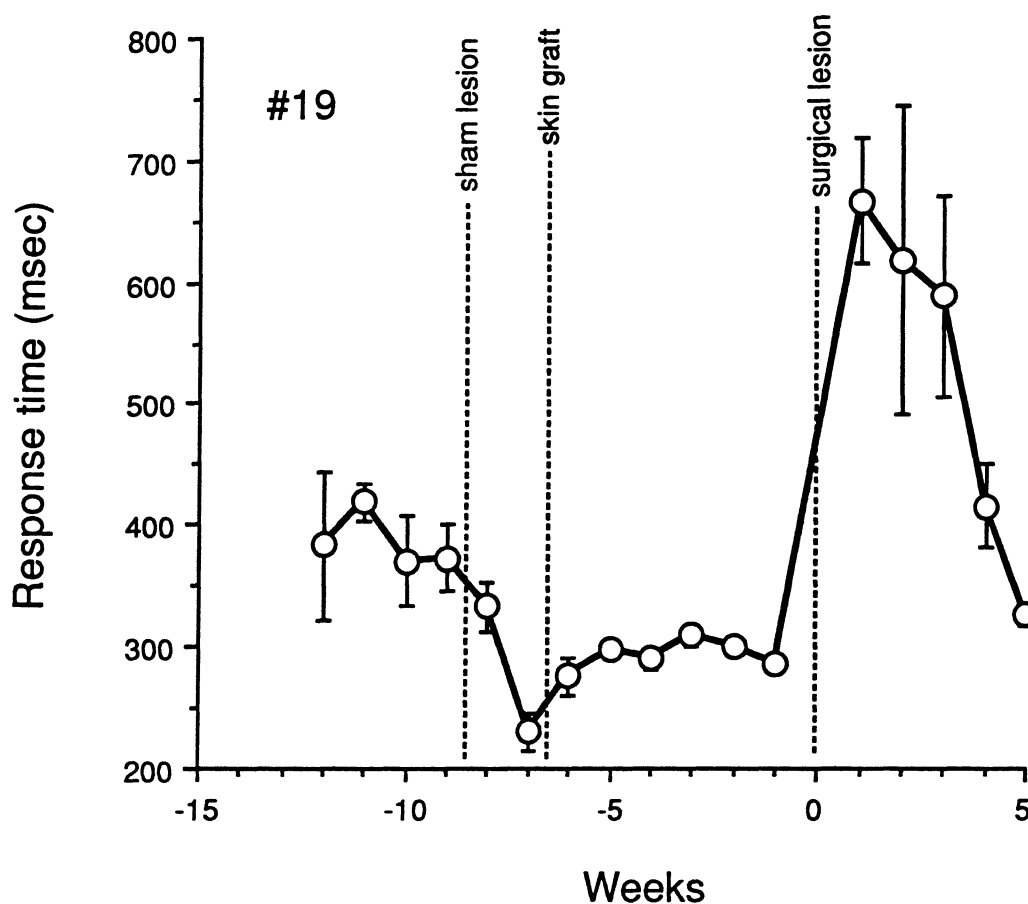


Fig. 4: Plot of motor performance of rat #19 during baseline condition and following a sham skin lesion, a skin graft, and surgical removal of its transplant. Since a MRI scan (Fig. 1A) showed that the skin graft did not produce immunological rejection of the transplant and since the skin graft did not produce behavioral effects for 6 weeks, the transplant was removed surgically. Note the immediate increase in IRTs following this procedure. Error bars indicate S.E.M. values.

Histological analysis

Histology showed that 2 of the 6 animals that received skin grafts, subjects #23 (Fig. 5A) and #33 (Fig. 1C,D) had their transplants entirely removed. Subjects #19 (Fig. 5C,D), #27, and #30 (not shown), had large transplants, and #22 (not shown) had remnants of transplanted tissue still present in their brains. It is noteworthy that subject #33, the only subject that showed behavioral deterioration following skin grafting, had its transplant successfully removed.

Residual transplants following attempted immunological rejections contained cellular infiltrates at the host-transplant margins (Fig. 5B). H&E stained sections showed that these cellular infiltrates were small blue staining lymphocytes (Fig. 5D, solid arrow). These cells were confined entirely to the transplants (Fig. 5B). In one subject (#27) the lymphocytes infiltrated the entire transplant (Fig. 5B), and in another (#19) the lymphocytes clustered around vessels within the transplant (Fig. 5C, solid arrow, D). Some transplants also had large, multinucleated cells that appeared to be macrophages (not shown).

All four rats that had their transplants removed surgically exhibited residues of transplanted tissue at the bottoms and sides of their brain cavities. Neurons and glia could be discerned within all residual transplants, but no clear histological differences were found between the host brains or transplants of subjects that exhibited behavioral deterioration compared to those that did not.

Histology of the brains of subjects that had transplants removed surgically demonstrated that normal cortex was not removed with the transplants and that host cortex was not injured in any subject. In addition, no evidence of cellular infiltration or other type of histological injury was found in the host brains of subjects in which transplant removals were attempted using immunological rejection.

DISCUSSION

The removal of transplants in 3 subjects led to significant deterioration in motor performance. We have shown /16/ that removal of forelimb motor/sensory cortex produces a similar effect in normal rats. Therefore we suggest that these

transplants functioned in a way analogous to normal cortex.

The explanation why the removal of these 3 transplants produced motor deficits while removal of transplants in the other subjects did not is uncertain. Transplant function could depend on the formation of neural interconnections between transplants and host brain. Pyramidal neurons in fetal cortex transplants project to newborn host thalamus, cortex, spinal cord /5,8,12,13,20,34/, and fibers from host thalamic and neocortical neurons synapse inside transplants /5,8,11,17,18,20,24/. It could be hypothesized that the neural connections between these 3 transplants and the host brains were more profuse. These connections, in turn, were either functional, or exerted a trophic effect on other structures of the host brain that participate in the lever pressing behavior.

The failure to produce behavioral deficits by surgically removing 2 grafts could be due to several factors. The residual transplant tissue that remained in the host brain cavities could explain this result. Alternatively, these transplants may have had very few interconnections with host brain, and their removal did not produce changes in the function of host brain. We have previously observed that degrees of transplant/host connectivity /18/ and the number of surviving neurons specifically stained for NADPH-d /17/, cholinesterase /24/ and neuropeptides /32/ can vary from animal to animal. Furthermore, some transplants exhibit decreased glucose metabolic rate /29/ and lower oxidative enzyme activity /28/ suggesting that their connections and cellular composition are abnormal. The fact that the removal of these transplants from the mature animals did not produce behavioral deficits, however, does not imply that they did not function. Other investigators have shown that while cortical grafts may have a beneficial effect on the performance of cognitive tasks, removing these grafts, once learning has occurred, does not produce behavioral deterioration /21/.

While immunological transplant removal was attempted in 6 subjects, only 2 grafts were successfully removed. It is noteworthy that behavioral deterioration occurred in one of these two subjects (Rat #33, Fig. 2, Table 1). The long delay between skin grafting and behavioral

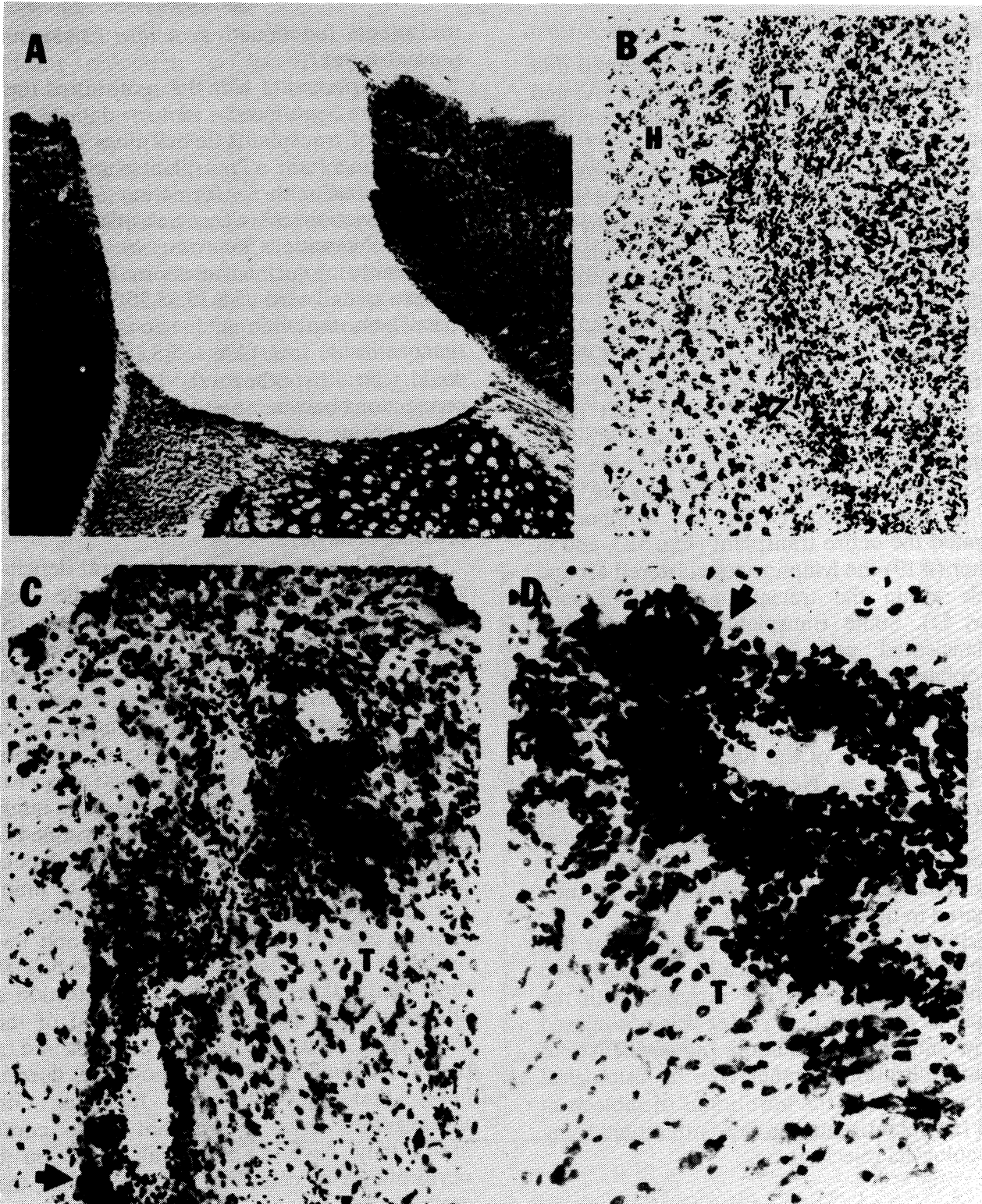


Fig. 5: (A) Nissl stained section of subject #23 showing the absence of a transplant in its cavity in motor cortex 6 weeks following skin grafting. (B) Hematoxylin and eosin stained section of subject #27 five weeks after receiving a skin graft to induce the immunological rejection of its transplant (T). Note the diffuse cellular infiltrate in T extending along the T-H margin (open arrows). (C and D) Sections of the transplant of subject #19 which was surgically removed after a MRI scan showed that a skin graft did not induce its rejection. Nissl staining (C) shows cellular infiltrates around blood vessels (solid arrow) which appear to be lymphocytes using H&E staining (D).

deterioration observed in this subject could be due to the delay of the actual removal of the graft *in situ*.

No evidence of behavioral deterioration occurred in five subjects that had surviving transplants following attempted removal using immunological rejection. If any of these grafts were actually functioning, the presence of inflammatory cells within the grafts apparently did not affect the motor function assessed in this study.

The reasons why we failed to immunologically remove most of the transplants are uncertain. Freed /14/ used similar methods to induce the immunological rejection of fetal substantia nigra grafts and observed behavioral deterioration in his subjects. Carder et al. /2/ recently used immunological rejection between species (rats and mice) to accomplish high rejection rates of transplanted dissociated dopaminergic neurons. It is possible that the success in the last case was related to a better immune attack taking place against groups of individual cells. Recent results indicate that transplants between species are more likely to be rejected, whereas transplants between rat strains are less likely to be rejected unless there are major immunological differences between the strains /9/.

In order to conclude that 3 subjects in this study had transplants that functioned by neural interactions with their host brains, it is necessary to establish that measuring IRTs is a valid way to assess cortical transplants' function. Even though this behavioral test utilizes quantified data unaffected by observer bias, it could not be argued that it is specific to motor cortex injury. Lesions of sensory cortex, substantia nigra, cerebellum and other structures are likely to increase IRTs as well. However, our previous work has shown that increases of IRTs are a sensitive index of injury confined to motor/sensory cortex in adult rats /16/. We suggest that the use of IRTs in this study was valid because (a) newborn rats sustained injury only to motor/sensory cortex, and (b) we took precautions to ensure that the removal of transplants never affected the host brain. Histological evidence showed that surgical removal of transplants never injured the surrounding host brain. In addition, lymphocytes or macrophages were never found in the host brains of subjects that received skin grafts, but

were confined to the transplants. Therefore, the behavioral deterioration observed in the three subjects could not be ascribed to host brain injury.

Neonatal rather than mature hosts were used in this study for several reasons. First, many pyramidal neurons in fetal cortical transplants project to neonatal host cortex, thalamus, pons, and spinal cord /6,7,12,13,20,34/ in comparison to the very few pyramidal neurons in fetal cortical transplants that project to adult host thalamus /18/ and by inference to other subcortical structures. Secondly, newborn motor/sensory cortex is more "plastic" than juvenile or adult cortex. Newborn cortical injury results in greater bilateral subcortical connections than adult cortical injury /3,4,15,25,30/. This greater plasticity might promote the formation of host-transplant interconnections in the newborn host. Thirdly, there is greater gliosis in transplants placed in juvenile compared to newborn hosts, suggesting that normal projections of cells are more likely to occur in transplants in newborn hosts /28/. Fourthly, fetal cortical transplants ameliorate the thalamic atrophy which occurs following frontal cortical lesions in the newborn host /31/. Finally, while grafts of cortical cells in injured frontal cortex of neonatal rats reduce some motor deficits /27/, cortical grafts in adult brains have produced deleterious /22/ or non-beneficial /10/ effects.

ACKNOWLEDGMENTS




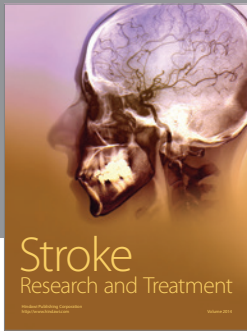

We wish to acknowledge the contributions of Janet Loken, Ann Poncelet, Matt Morton, Mark Mandabach, Pat Jasper, and Theresa Marsh. The research was supported by grants from the Research Service of the Veterans Administration, the National Institutes of Health (NS 24666), and the United Cerebral Palsy Foundation (354-87).

REFERENCES

1. Arendash GW, Mouton PR. Transplantation of nucleus basalis magnocellularis cholinergic neurons into the cholinergic-depleted cerebral cortex:

- morphological and behavioral effects. *Ann NY Acad Sci* 1987; 495: 431-443.
2. Carder RK, Snyder-Keller AM, Lund RD. Behavioral and anatomical correlates of immunologically induced rejection of nigral xenografts. *J Comp Neurol* 1988; 277: 391-402.
 3. Castro AJ. Ipsilateral corticospinal projections after large lesions of the cerebral hemisphere in neonatal rats. *Exp Neurol* 1975; 46: 1-8.
 4. Castro AJ, Mihailoff GA. Corticopontine remodeling after cortical and/or cerebellar lesions in newborn rats. *J Comp Neurol* 1983; 219: 112-123.
 5. Castro AJ, Tønder N, Sunde NA, Zimmer J. Fetal cortical transplants in the cerebral hemisphere of newborn rats: A retrograde fluorescent analysis of connections. *Exp Brain Res* 1987; 66: 533-542.
 6. Castro AJ, Tønder N, Sunde NA, Zimmer J. Fetal neocortical transplants grafted to the cerebral cortex of newborn rats receive afferents from the basal forebrain, locus coeruleus and midline raphe. *Exp Brain Res* 1988; 69: 613-622.
 7. Castro AJ, Zimmer J, Sunde NA, Bold EL. Transplantation of fetal cortex to the brain of newborn rats: A retrograde fluorescent analysis of callosal and thalamic projections from transplant to host. *Neurosci Lett* 1985; 60: 283-288.
 8. Chang F-LF, Steedman JG, Lund RD. The lamination and connectivity of embryonic cerebral cortex transplanted into newborn rat cortex. *J Comp Neurol* 1986; 244: 401-411.
 9. Date I, Kawamura K, Nakashima H. Histological signs of immune reactions against allogeneic solid fetal neural grafts in the mouse cerebellum depend on the MHC locus. *Exp Brain Res* 1988; 73: 15-22.
 10. Dunnett SB, Ryan CN, Levin PD, Reynolds M, Bunch ST. Functional consequences of embryonic neocortex transplanted to rats with prefrontal cortex lesions. *Behav Neurosci* 1987; 101: 489-503.
 11. Ebner FF. The development of functional connections between transplanted embryonic and mature cortical neurons. In: Gash DM, Sladek JR, eds, *Progress in Brain Research*, Vol. 78, Transplantation into the Mammalian CNS. Amsterdam: Elsevier, 1988; 3-11.
 12. Floeter MK, Jones EG. Connections made by transplants to the cerebral cortex of rat brains damaged *in utero*. *J Neurosci* 1984; 4: 141-150.
 13. Floeter MK, Jones EG. Transplantation of fetal postmitotic neurons to rat cortex: survival, early pathway choices and long-term projections of outgrowing axons. *Develop Brain Res* 1985; 22: 19-38.
 14. Freed WJ. Functional brain tissue transplantation: Reversal of lesion-induced rotation by intraventricular substantia nigra and adrenal medulla grafts, with a note on intracranial retinal grafts. *Biol Psychiat* 1983; 18: 1205-1267.
 15. Goldman PS. Neuronal plasticity in primate telencephalon: Anomalous projections induced by prenatal removal of frontal cortex. *Science* 1978; 202: 768-770.
 16. Gonzalez MF, Poncelet A, Loken JE, Sharp FR. Quantitative measurement of interresponse times to assess forelimb motor function in rats. *Behav Brain Res* 1986; 22: 75-84.
 17. Gonzalez MF, Sharp FR. Fetal frontal cortex transplanted to injured motor/sensory cortex of adult rats. I. NADPH-diaphorase neurons. *J Neurosci* 1987; 7: 2991-3001.
 18. Gonzalez MF, Sharp FR, Loken JE. Fetal frontal cortex transplanted to injured motor/sensory cortex of adult rats: Reciprocal connections with host thalamus demonstrated with WGA-HRP. *Exp Neurol* 1988; 99: 154-165.
 19. Hayes CE, Edelstein WA, Schenk JF, Mueller OM, Eash M. An efficient, highly-homogeneous radiofrequency coil for whole body NMR imaging at 1.5T. *J Magnetic Resonance* 1985; 63: 622-626.
 20. Jaeger CB, Lund RD. Transplantation of embryonic occipital cortex to the tectal region of newborn rats: a light microscopic study of the organization and connectivity of the transplants. *J Comp Neurol* 1980; 194: 571-597.
 21. Kesslak JP, Nieto-Sampedro M, Globus J, Cotman CW. Transplants of purified astrocytes promote behavioral recovery after frontal cortex ablation. *Exp Neurol* 1986; 92: 377-390.
 22. Kolb B, Reynolds B, Fantie B. Frontal cortex grafts have opposite effects at different postoperative recovery times. *Behav Neural Biol* 1988; 50: 193-206.
 23. Labbe R, Firl A, Mufson EJ, Stein DG. Fetal brain transplants: Reduction of cognitive deficits in rats with frontal cortex lesions. *Science* 1983; 221: 470-472.
 24. Mampalam TJ, Gonzalez MF, Weinstein P, Sharp FR. Neuronal changes in fetal cortex transplanted to ischemic adult rat cortex. *J Neurosurg* 1988; 69: 904-912.
 25. Mihailoff GA, Castro AJ. Autoradiographic and electron microscopic evidence for axonal sprouting in the rat corticopontine system. *Neurosci Lett* 1981; 21: 267-273.
 26. Nicholas MK, Antel JP, Stefansson K, Arnason BGW. Rejection of fetal neocortical neural transplants by H-2 incompatible mice. *J Immunol* 1987; 139: 2275-2283.
 27. Plumet J, Cadusseau J, Roger M. Fetal cortical transplants reduce motor deficits resulting from neonatal damage to the rat's frontal cortex. *Neurosci Lett* 1990; 109: 102-106.
 28. Sandor R, Gonzalez MF, Loken J, Walicke PA, Sharp FR. Survival and succinate dehydrogenase and cytochrome oxidase staining of fetal frontal cortex transplants: Effects of host age and fibroblast growth factor. *J Neurotransplant* 1990.
 29. Sharp FR, Gonzalez MF. Fetal frontal cortex transplant [¹⁴C] 2-deoxyglucose uptake and histology: survival in cavities of host rat brain motor cortex. *Neurology* 1984; 34: 1305-1311.
 30. Sharp FR, Gonzalez MF. Adult rat motor cortex connections to thalamus following neonatal and juvenile frontal cortical lesions: WGA-HRP and

- amino acid studies. *Develop Brain Res* 1986; 30: 169-187.
31. Sharp FR, Gonzalez MF. Fetal cortical transplants ameliorate thalamic atrophy ipsilateral to neonatal frontal cortex lesions. *Neurosci Lett* 1986; 71: 247-251.
 32. Sharp FR, Gonzalez MF, Sagar SM. Fetal frontal cortex transplanted to injured motor/sensory cortex of adult rats. II. VIP-, Somatostatin-, and NPY-immunoreactive neurons. *J Neurosci* 1987; 7: 3002-3015.
 33. Slavin MD, Held JM, Basso DM, Lesensky S, Curran E, Gentile AM, Stein DG. Fetal brain tissue transplants and recovery of locomotion following damage to sensorimotor cortex in rats. In Gash DM, Sladek JR, eds, *Progress in Brain Research*, Vol. 78, Transplantation into the Mammalian CNS. Amsterdam: Elsevier, 1988; 33-38.
 34. Stanfield BB, O'Leary DDM. Fetal occipital cortical neurones transplanted to the rostral cortex can extend and maintain a pyramidal tract axon. *Nature* 1985; 313: 135-137.
 35. Streilein JW. Transplantation immunobiology in relation to neural grafting: Lessons learned from immunologic privilege in the eye. *Int J Devel Neurosci* 1988; 6: 497-511.
 36. Welner SA, Dunnett SB, Salamone JD, MacLean B, Iversen SD. Transplantation of embryonic ventral forebrain grafts to the neocortex of rats with bilateral lesions of nucleus basalis magnocellularis ameliorates a lesion-induced deficit in spatial memory. *Brain Res* 1988; 463: 192-197.



Hindawi

Submit your manuscripts at
<http://www.hindawi.com>

